

Sommerschule, école d'été 2017

25.08.2017

diagnostic imaging in H&N tumours

P

Prof. Dr. Bernhard Schuknecht, Medizinisch Radiologisches Institut Zürich (MRI)
bschuknecht@mri-roentgen.ch

PD Dr. Gerhard F. Huber, USZ
gerry.huber@usz.ch

Order of „business“

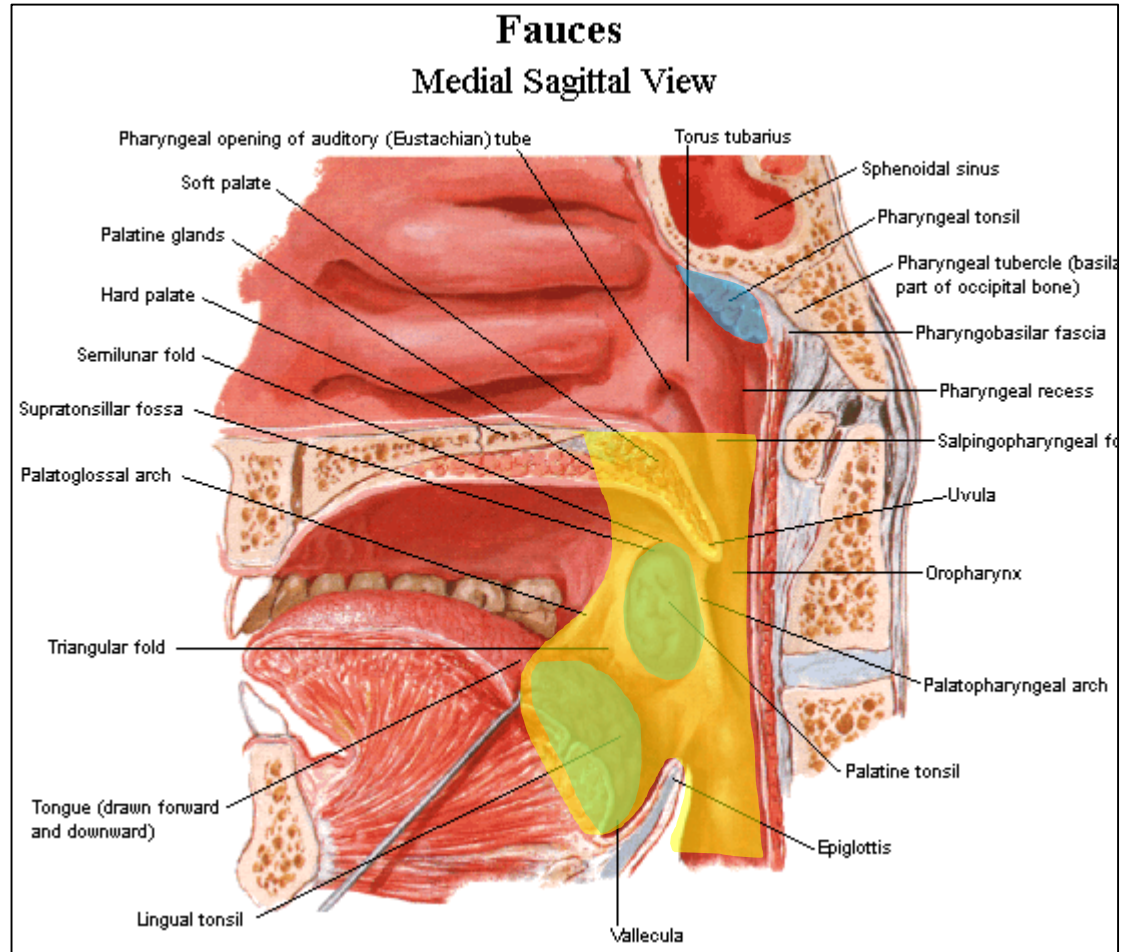
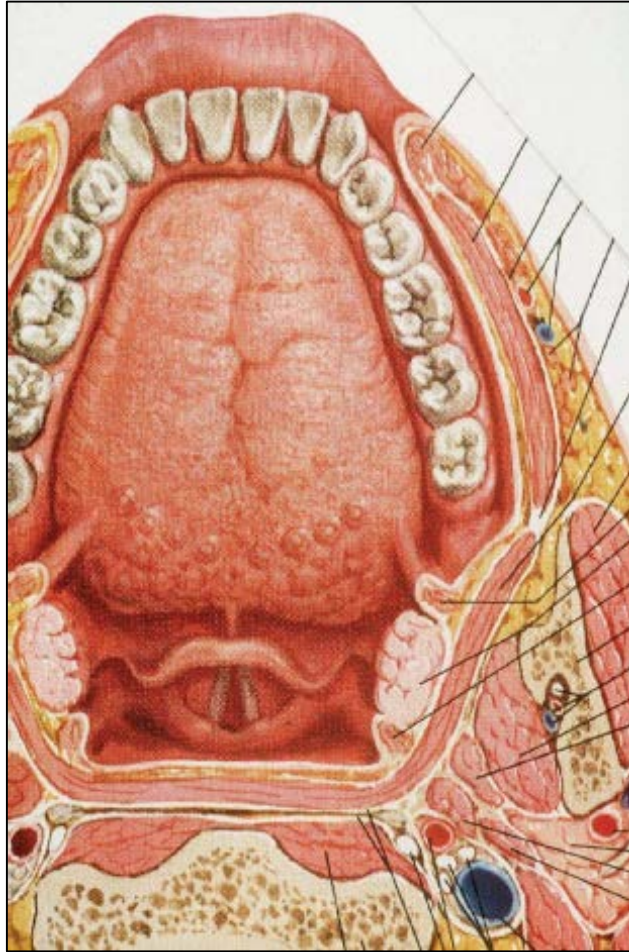
- **morphologic and «advanced " diagnostic imaging**
- supra- & infrahyoid pharyngeal- and neck-spaces !

locations

oral cavity
oropharynx
larynx
hypopharynx
(nasopharynx)

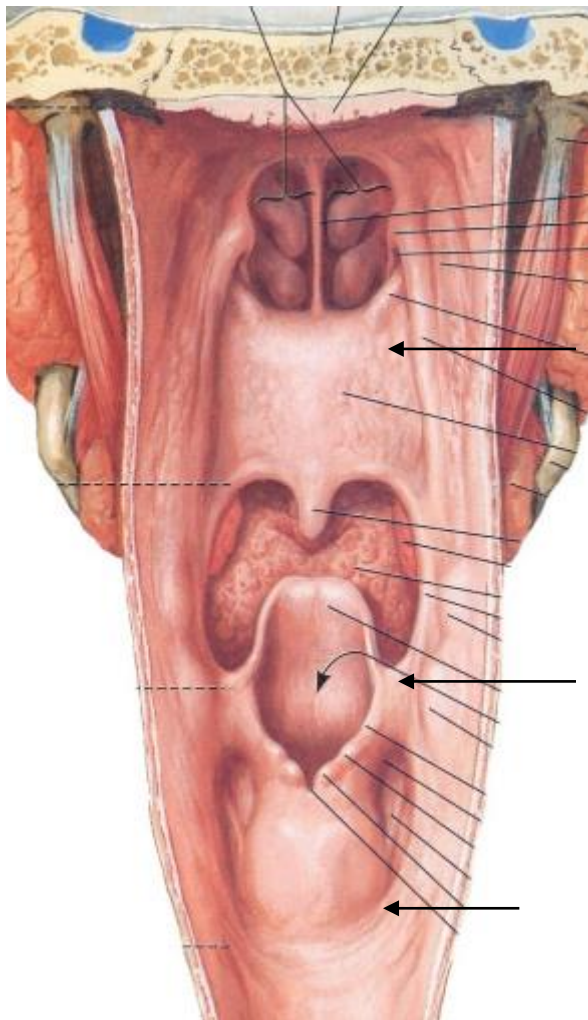
- salivary glands => parotid gland
- parapharyngeal space
- masticator space
- carotid space
- perineural spread

anatomy of the oral cavity and oropharynx



anatomic division of the pharynx

naso-(epi), meso- (oro), hypopharynx



nasopharynx

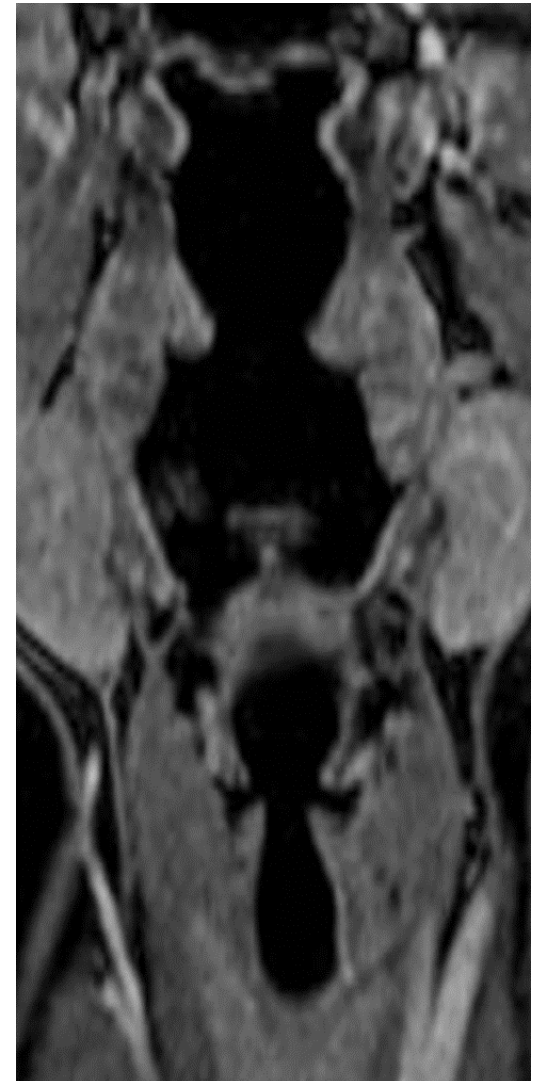skull base – soft palate

oropharynx

soft palate – pharyngo-epiglottic fold

Hypopharynx

- cricopharyngeus m.



deep cervical fascia

= key for understanding H&N
Anatomy

deep cervical fascia →

- superficial layer
- middle
- deep

divides neck in

spaces

suprahyoidal ↔ infrahyoidal

fasciae: probability of different tumours

relevance for surgical treatment?

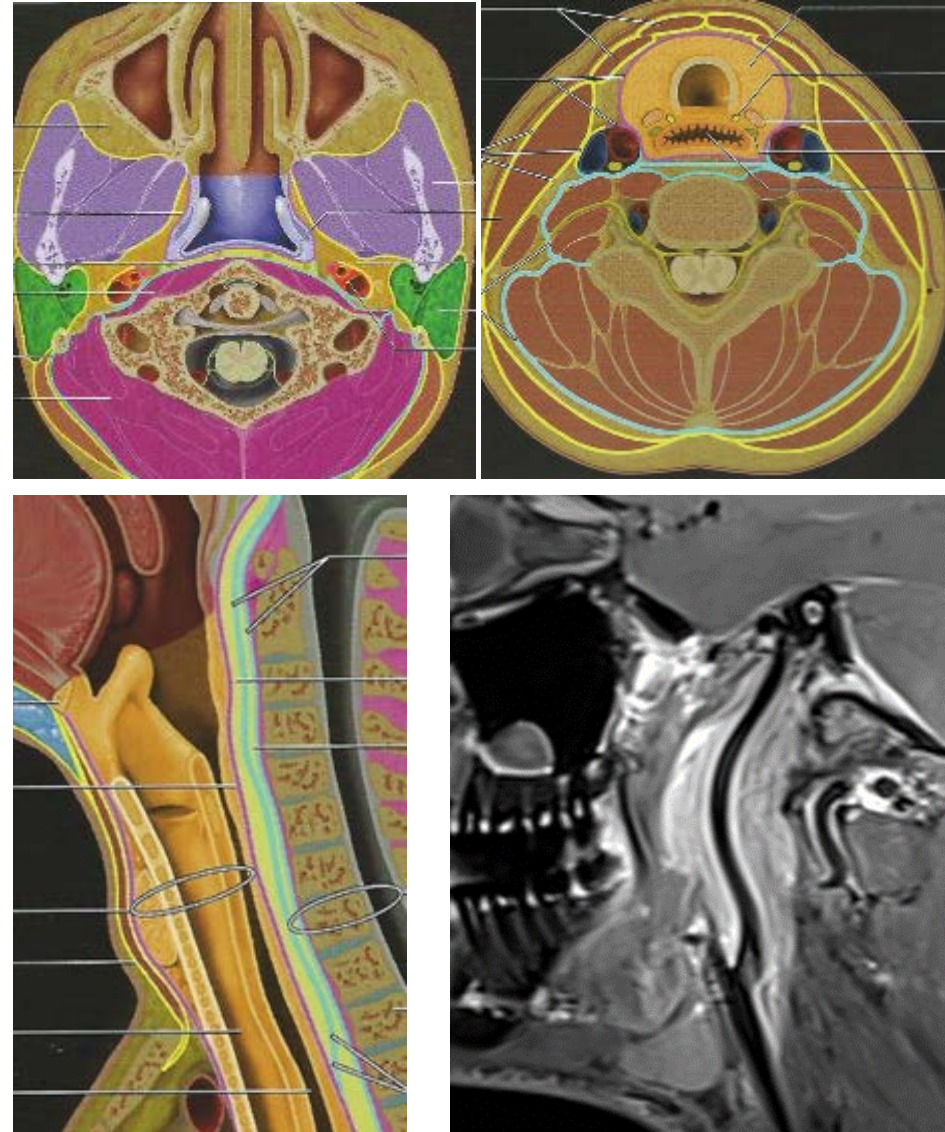
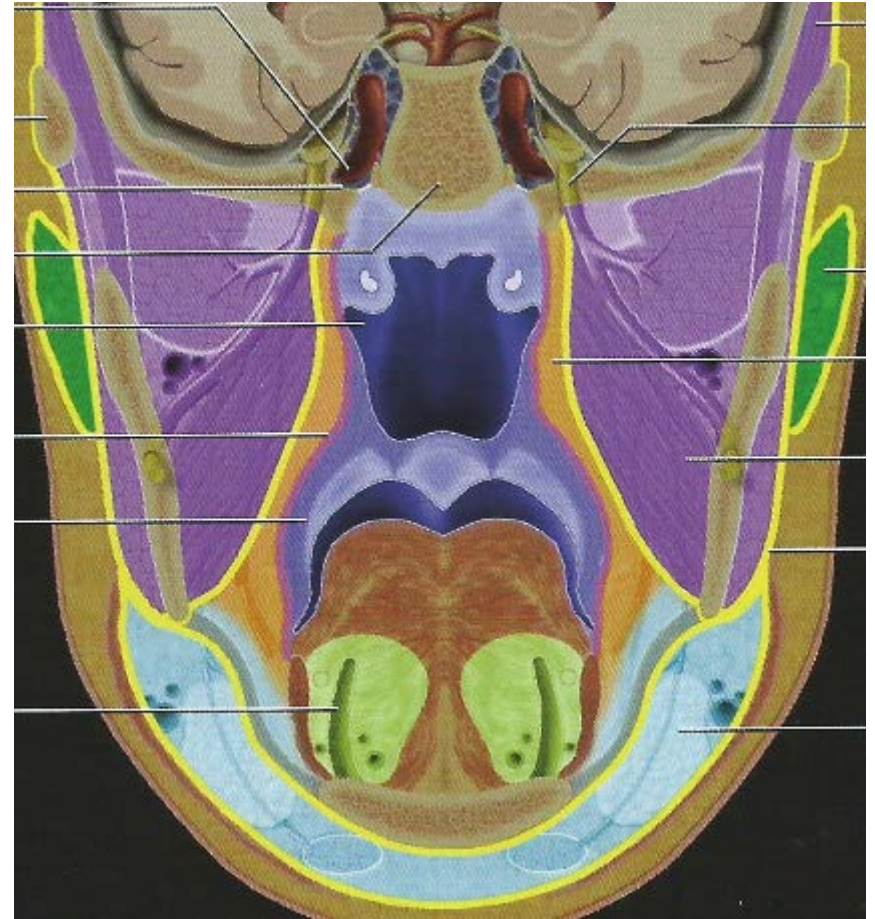
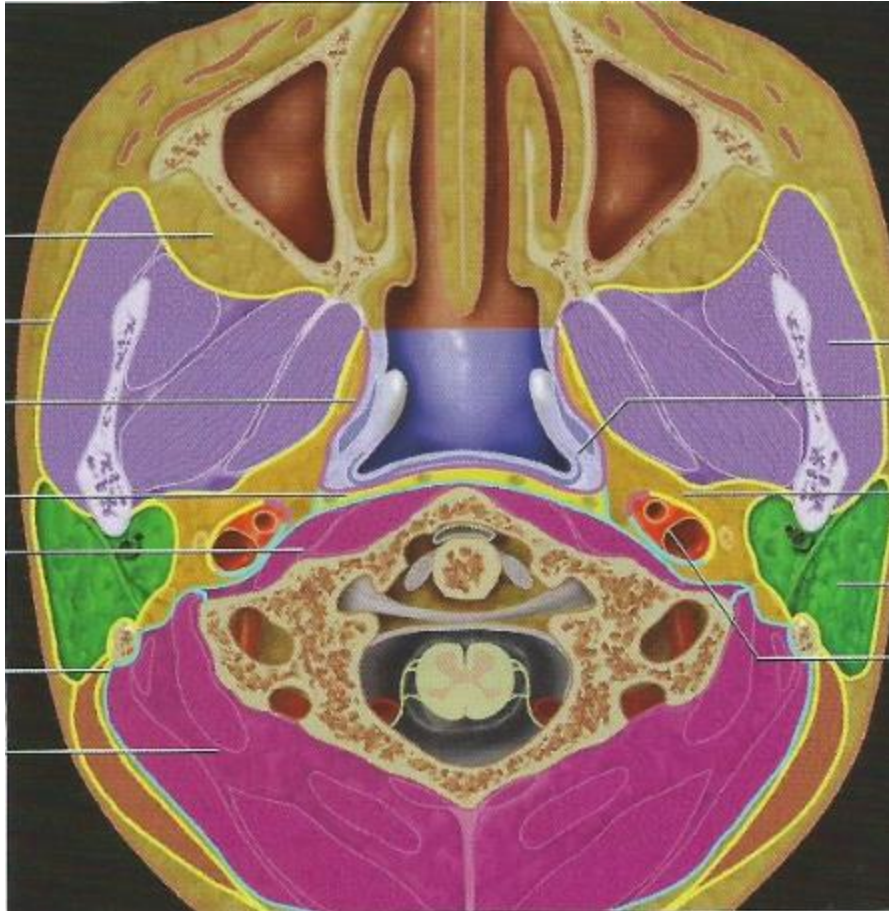


Fig. Harnsberger Ed. Diagnostic Imaging Head and Neck 2nd ed : Amirsys 2011

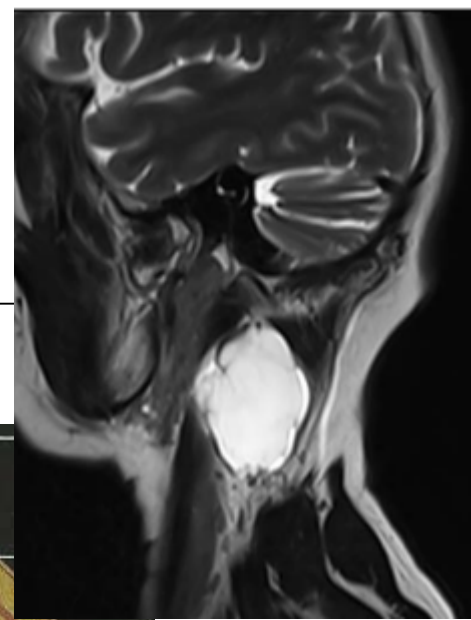
suprahyoidal

superficial : parotid-, masticator-, submandibular- space, parapharyngeal- & carotid- space

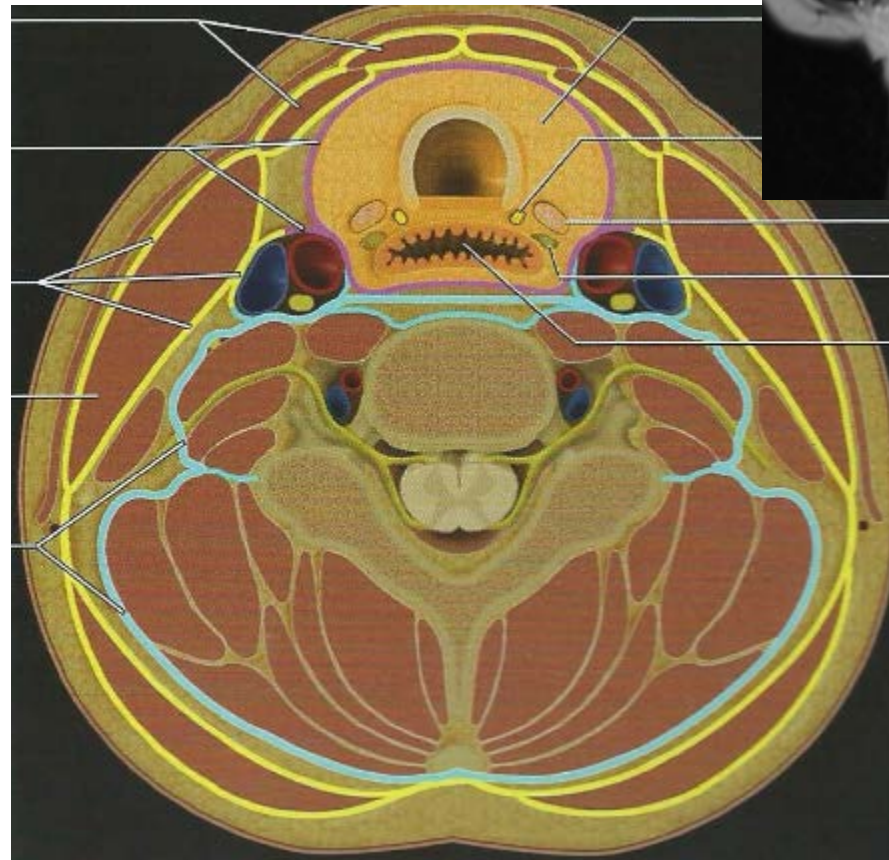

middle: pharyngeal mucosal space, retropharyngeal space
depp: retropharyngeal space, prevertebral space

infrahyoidal

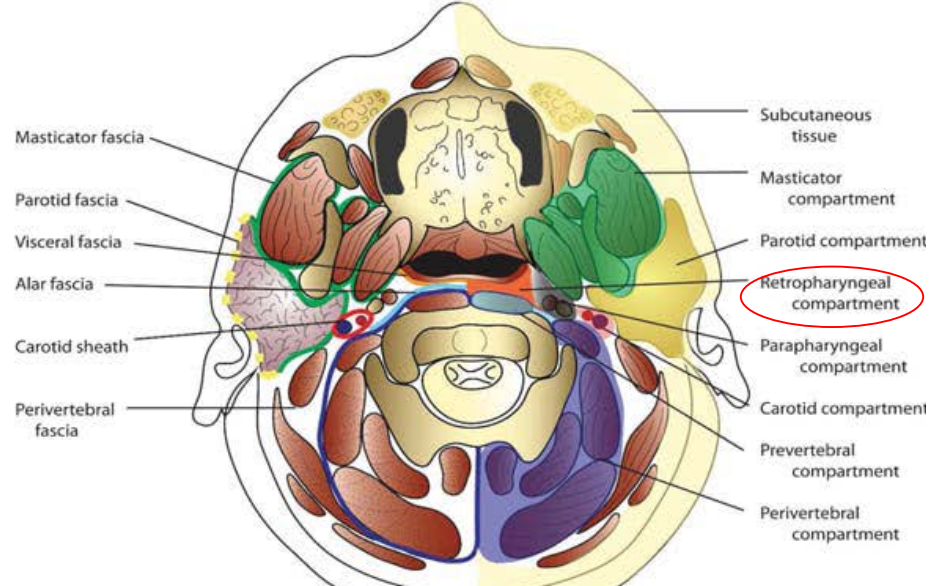


- **infrahyoidal**
 - visceral space
 - anterior cervical space
- **supra- /infrahyoidal**
 - carotid space
 - retropharyngeal / «danger» space
 - pre- (peri-)vertebral space
 - posterior cervical space

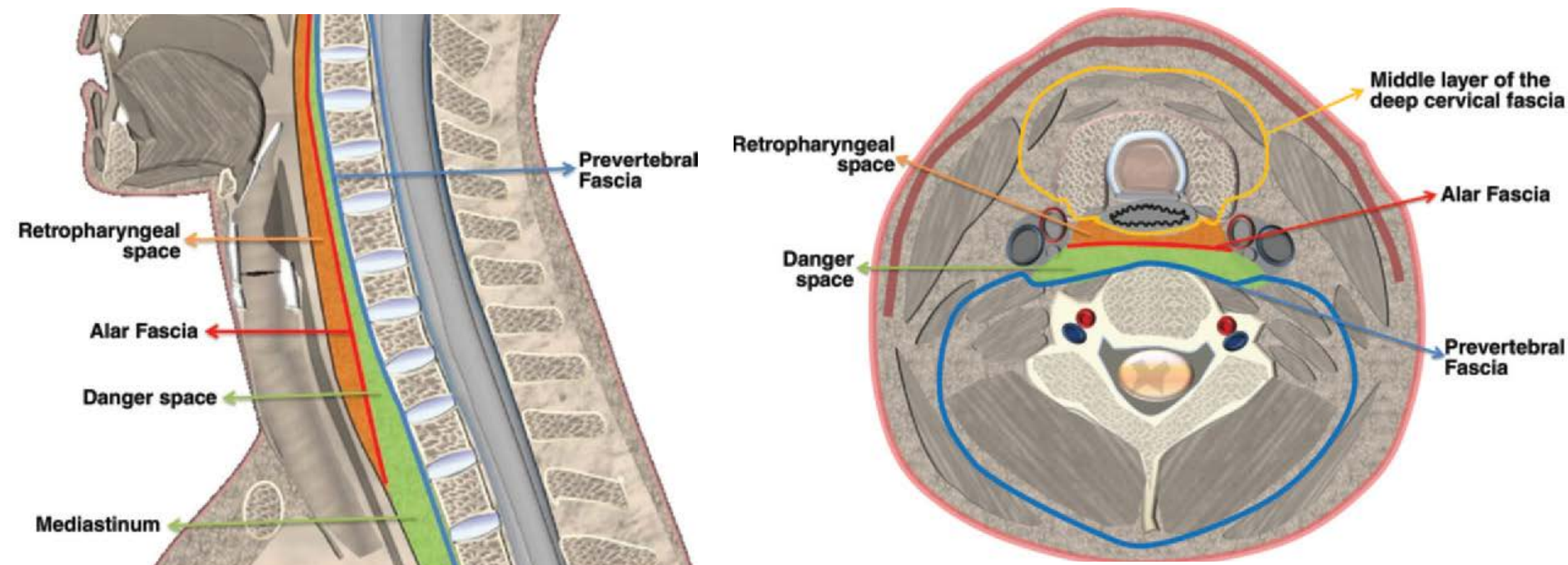


Spaces ?

Retropharyngeal + danger space
= *Retropharyngeal compartment*



Guidera AK et al. Head and neck fascia and compartments: No space for spaces. HEAD & NECK—DOI 10.1002/HED 2014



Katabathina V et al. Nonvascular, Nontraumatic mediastinal emergencies in adults: a comprehensive review of imaging findings. RadioGraphics 2011; 31:1141–1160

tasks of diagnostic imaging

relevant information for therapy planning

1. tumour location ?

initial starting point → e.g. tonsil vs adjacent mesopharynx

2. tumorextension ?

infiltration into deep, breaching of midline, bone- cartilage-, nerve-, vascular- involvement

3. involvement of lymph nodes?

cervical, retropharyngeal, mediastinal - fascial (parotid)

criteria - staging !

4. course during and after therapy

local, systemic, surgical

role of diagnostic imaging

different questions in different phases of treatment


diagnosis



treatment



follow-up



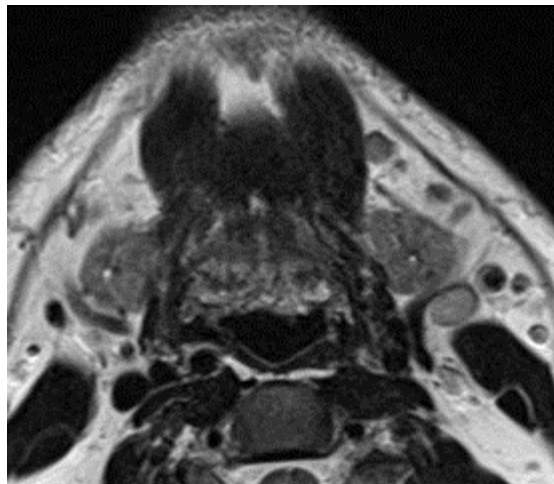
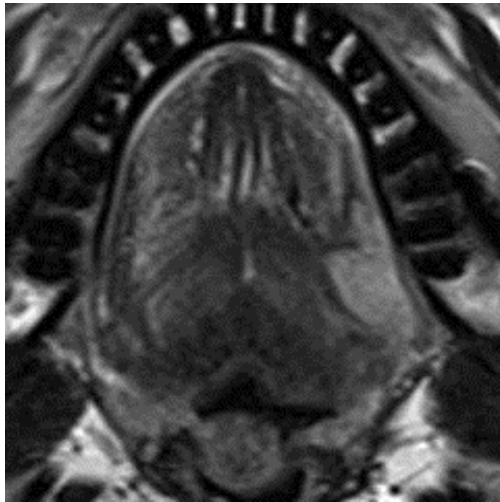
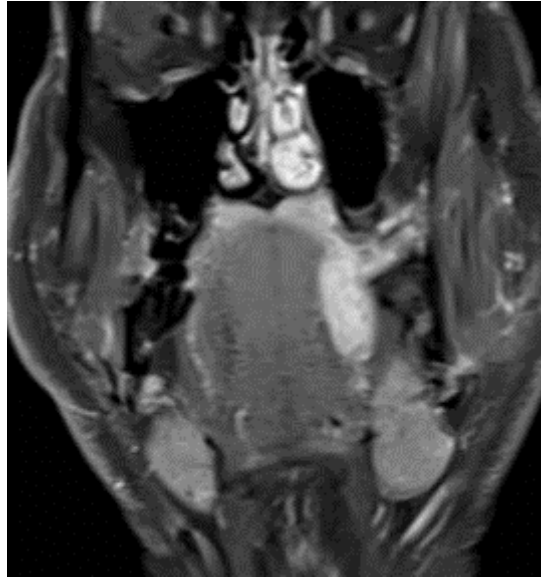Staging : mesopharynx and oral cavity

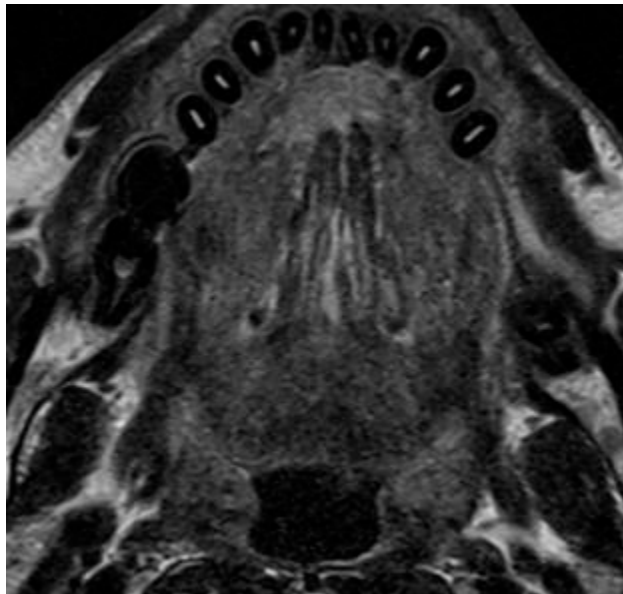
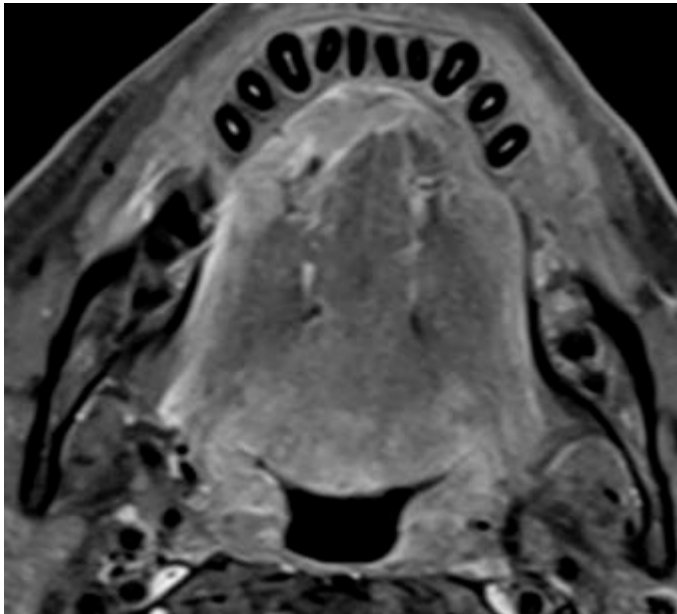
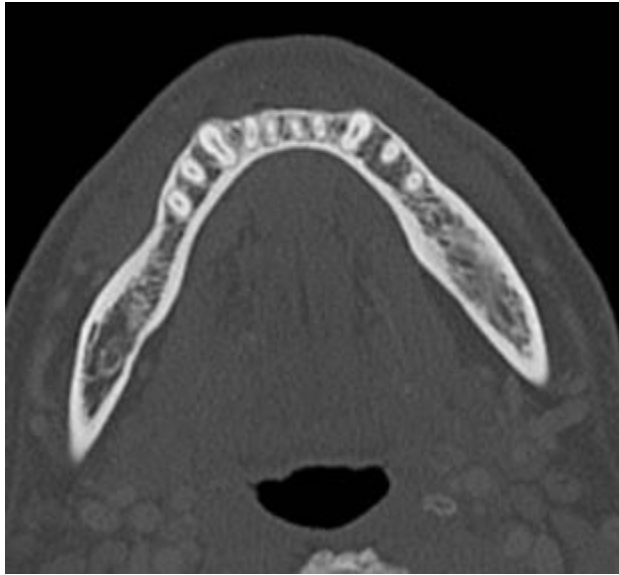
- **T1 Tu \leq 2 cm maximum diameter**
- **T2 Tu $>$ 2 cm \leq 4 cm maximum diameter**
- **T3 Tu $>$ 4 cm maximum diameter**
- **T4a Tu infiltrating supragl. larynx, extrinsic musculature,
potentially resectable**
- **T4b Tu infiltrating masticator space, skull base, ICA**

carcinoma of the oral cavity

- lower lip > tongue > FOM
- involvement of LN: 30-70% initially
- prognosis: ↓ anterior tw posterior
- crossing the midline
- infiltration of extrinsic tongue musculature, bone or supraglottic larynx

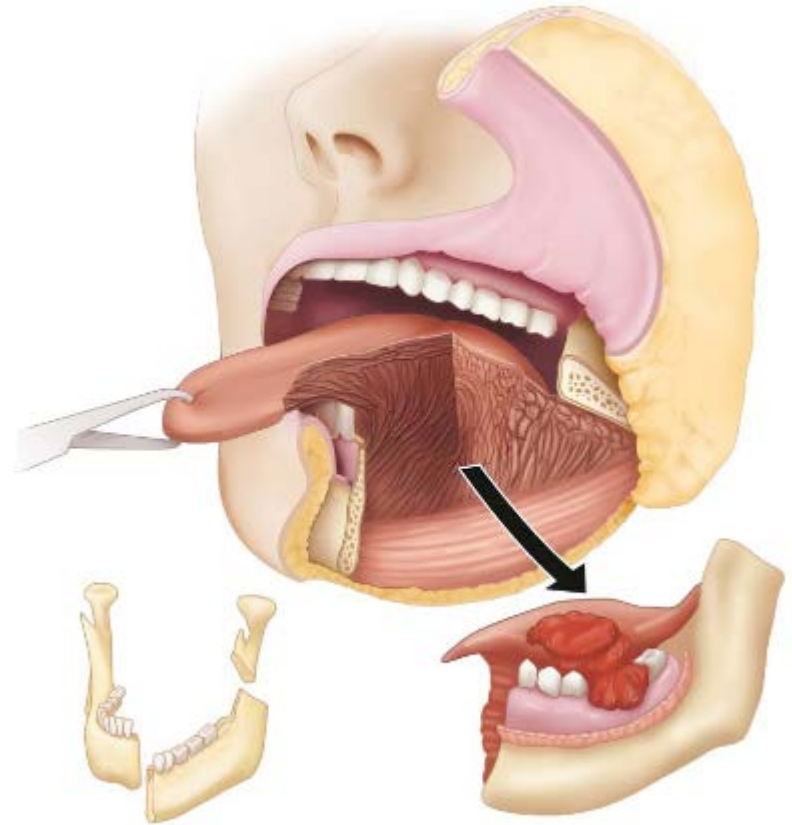
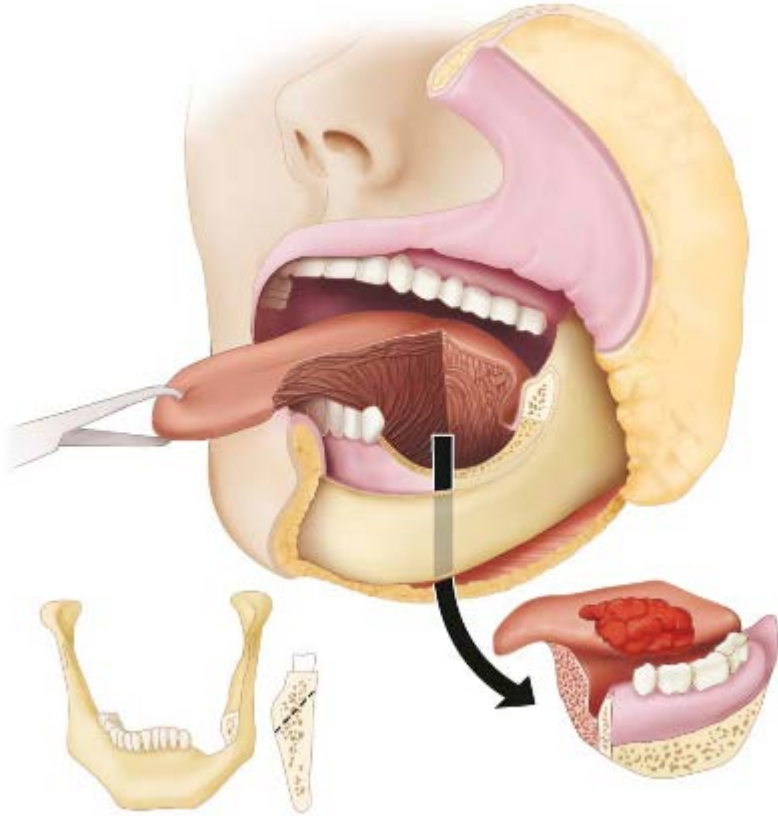
tongue cancer



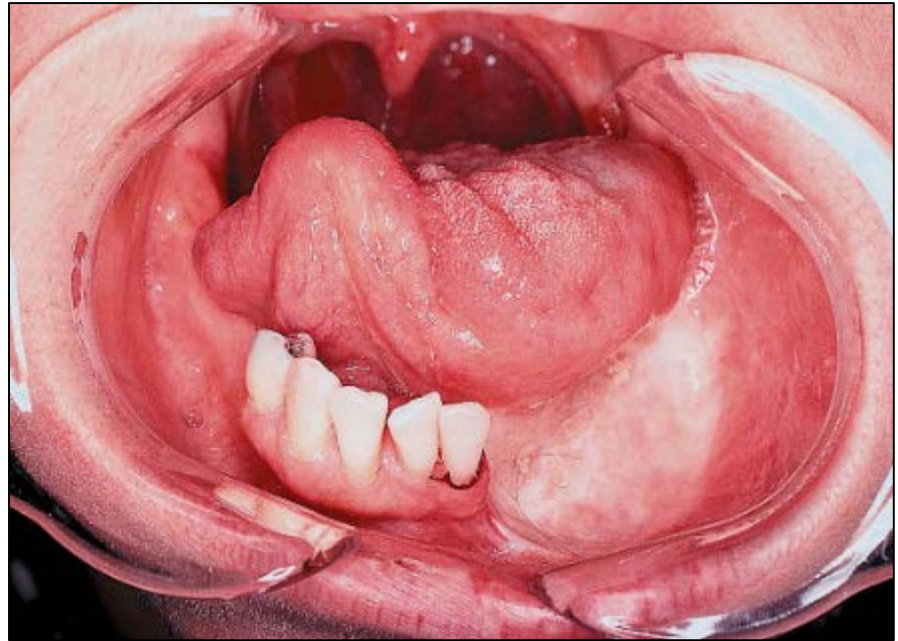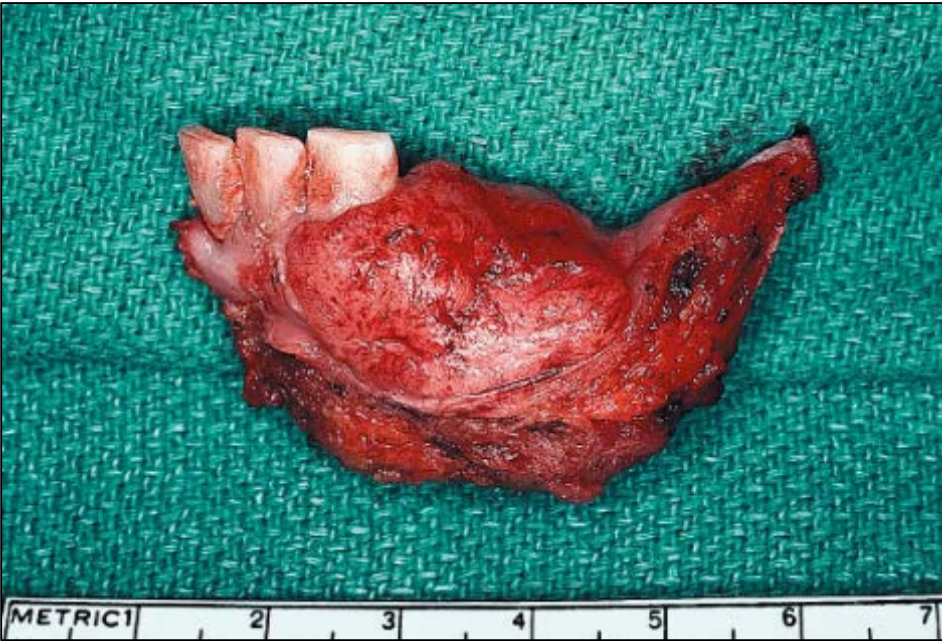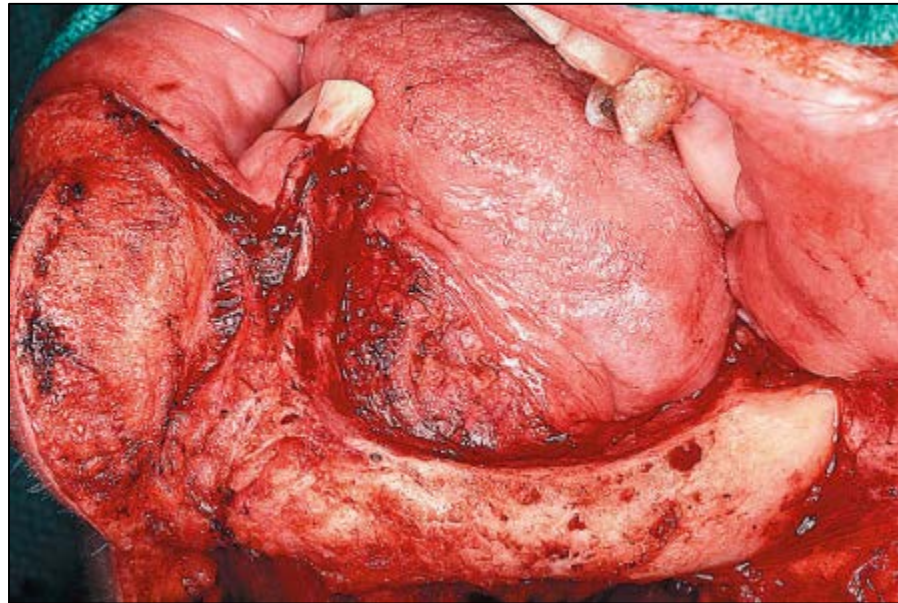
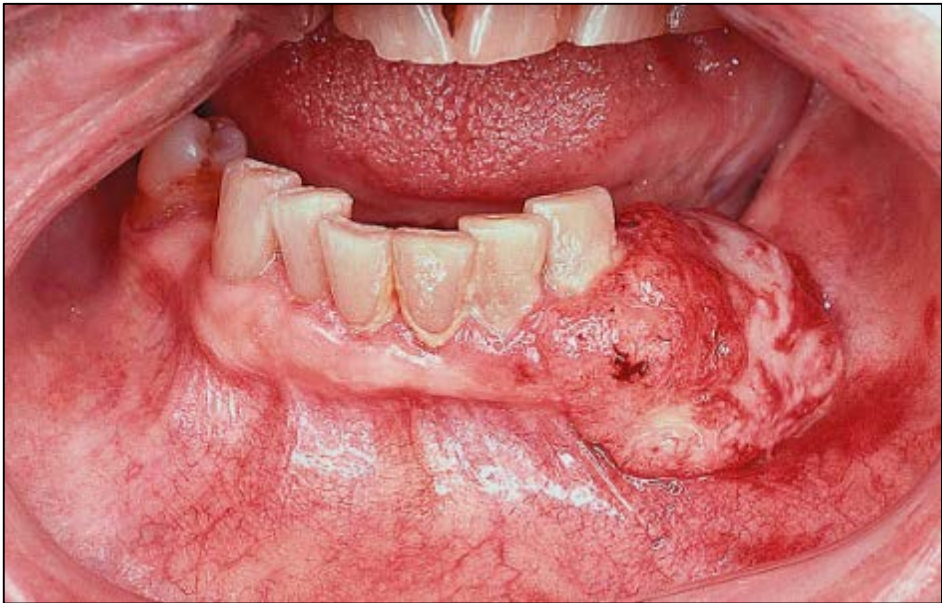


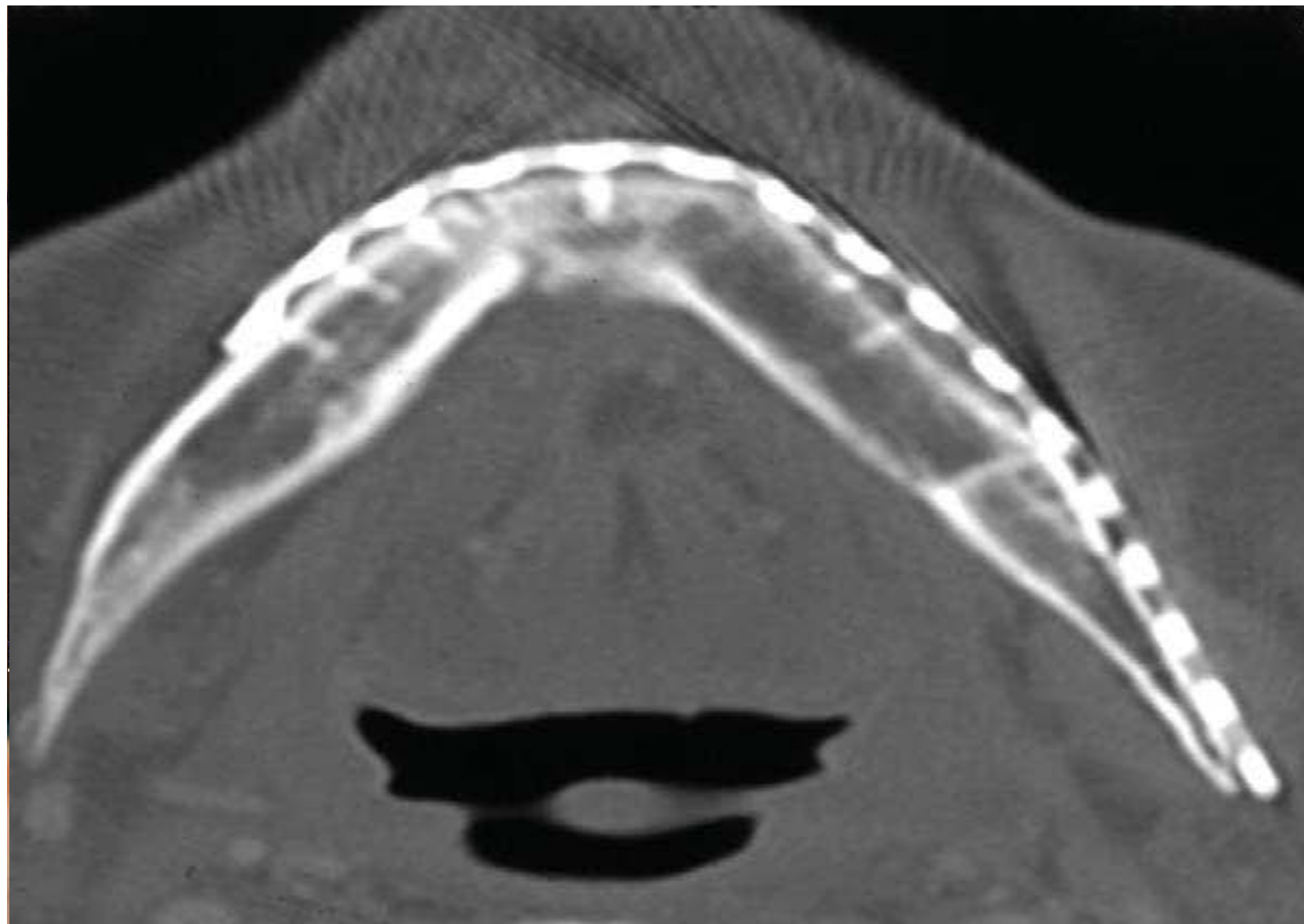
Floor of Mouth Ca
T2, N1

marginal mandibulectomy



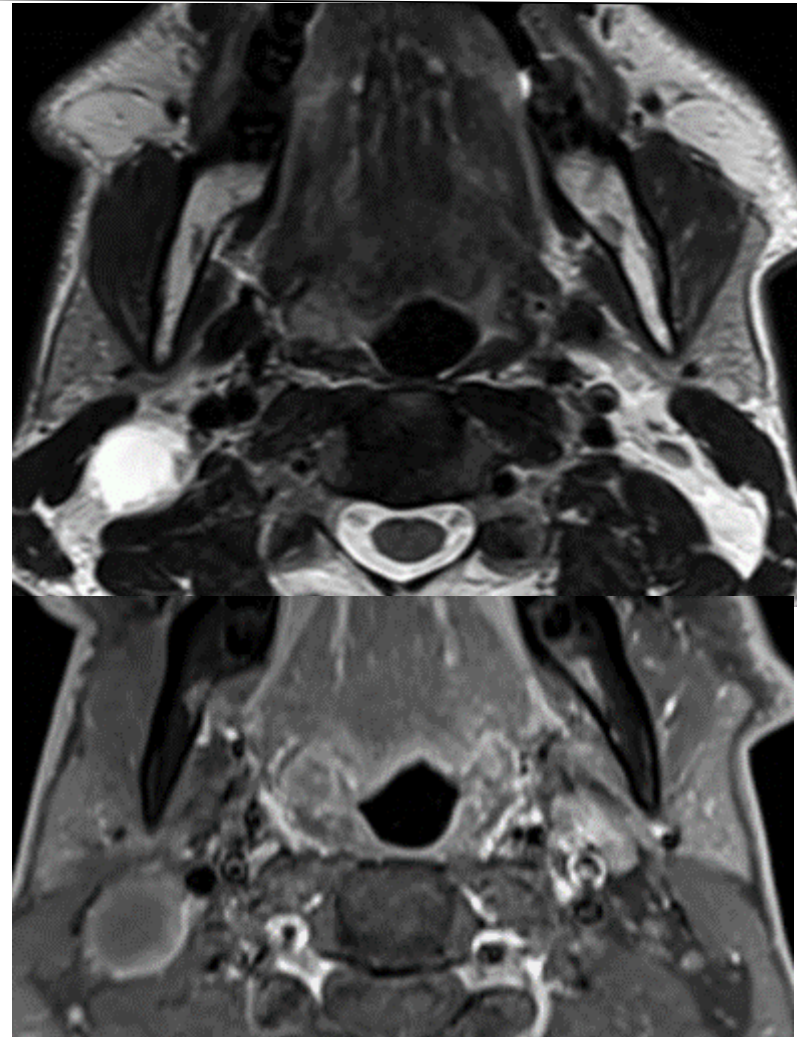
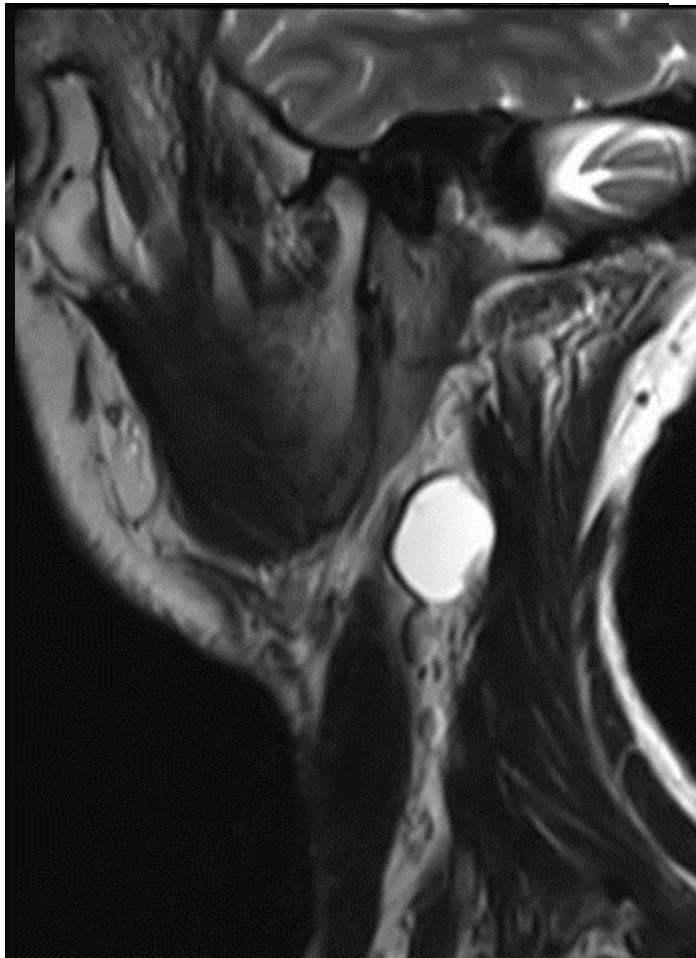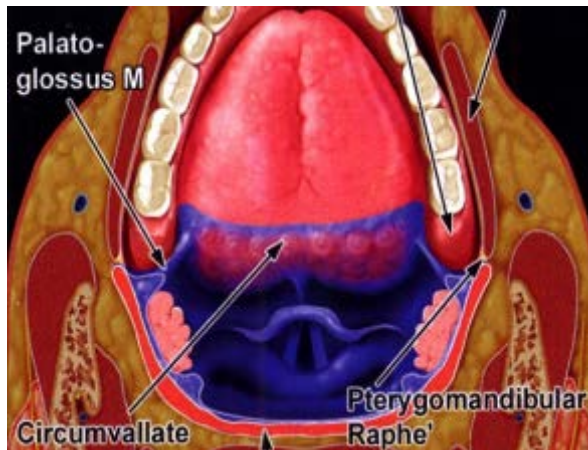
segmental mandibulectomy





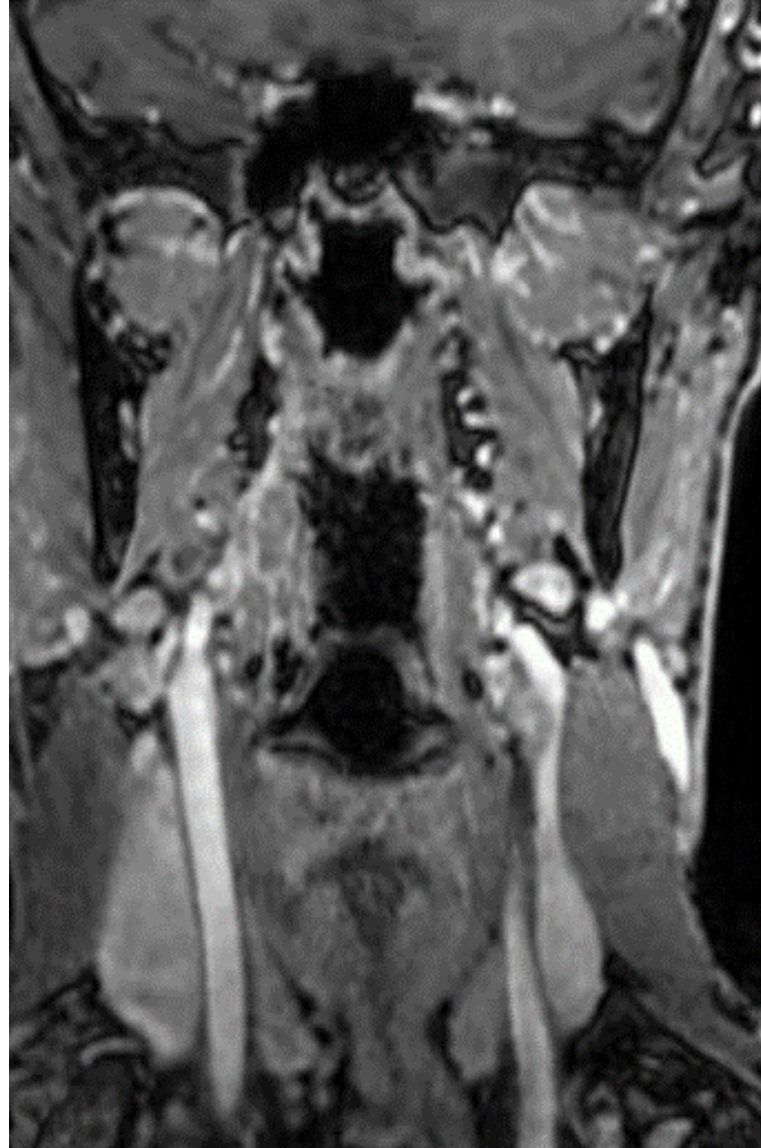
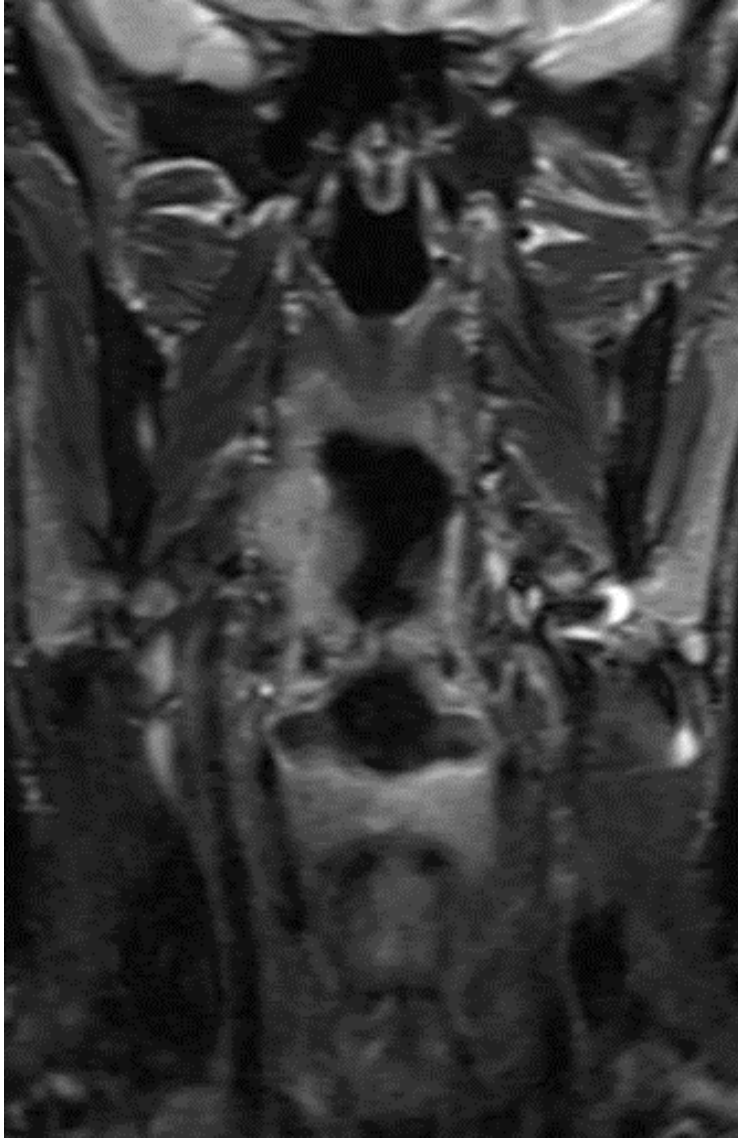Mesopharynx

neoplasms
tonsil 50%,
base of tongue 20%,
soft palate 10%
pharyngeal wall 10%



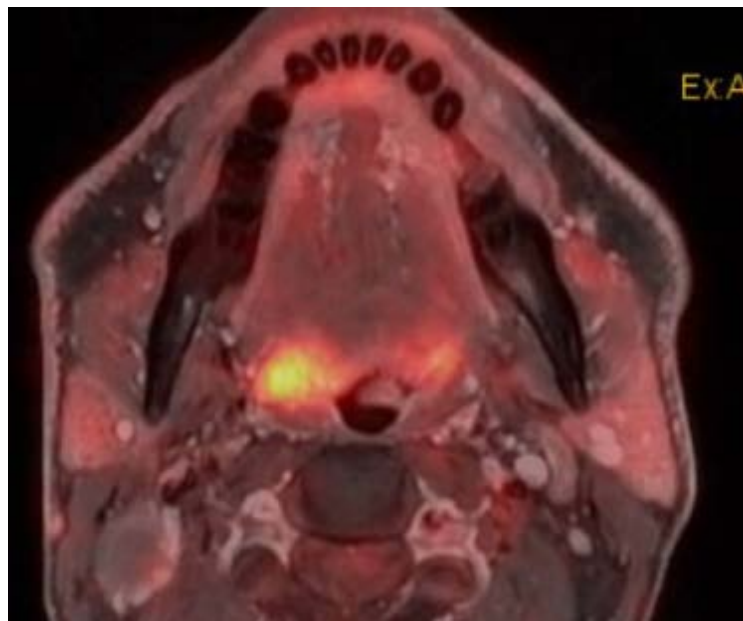
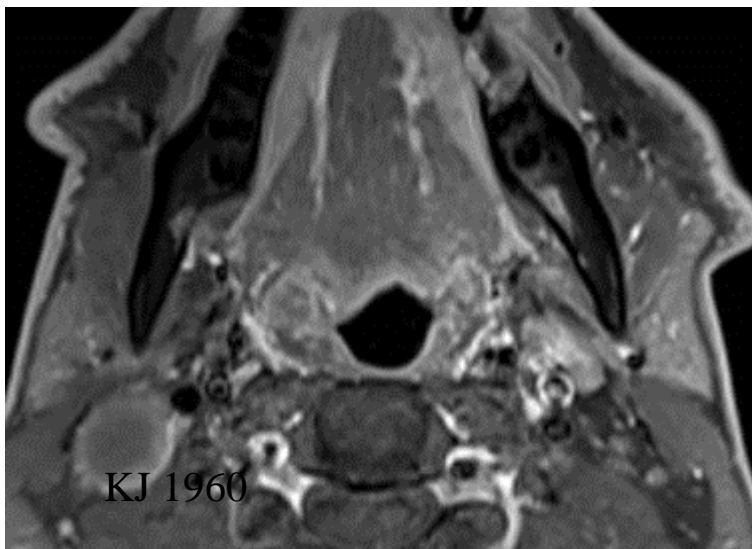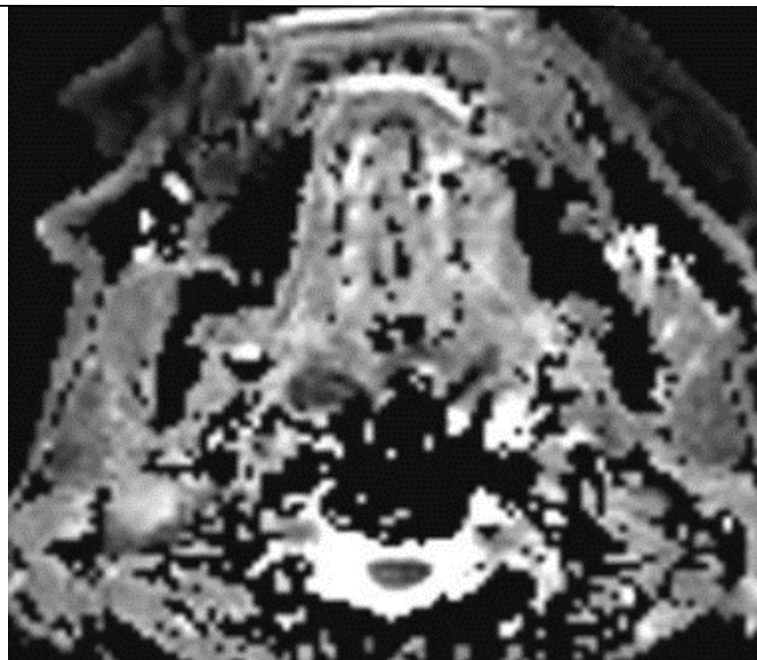
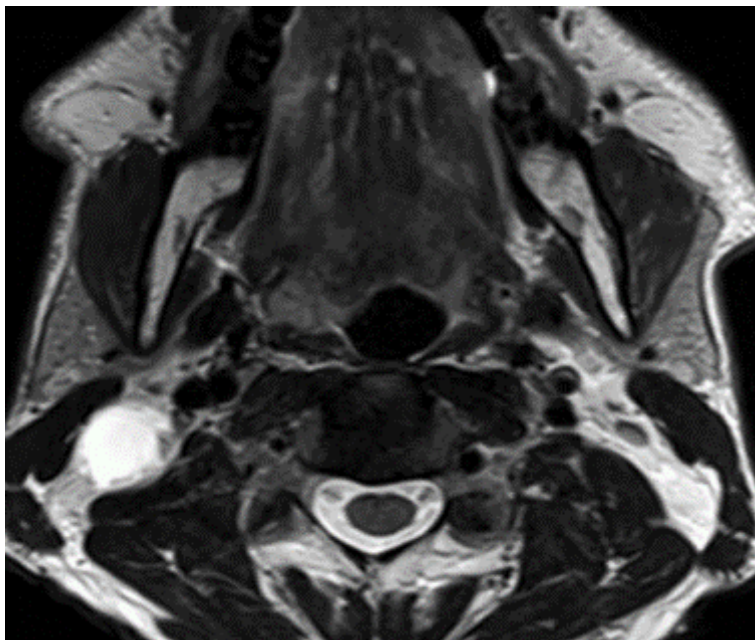
54y,m; lump on right mandibular angle, ↑ 4 weeks

Mesopharynx

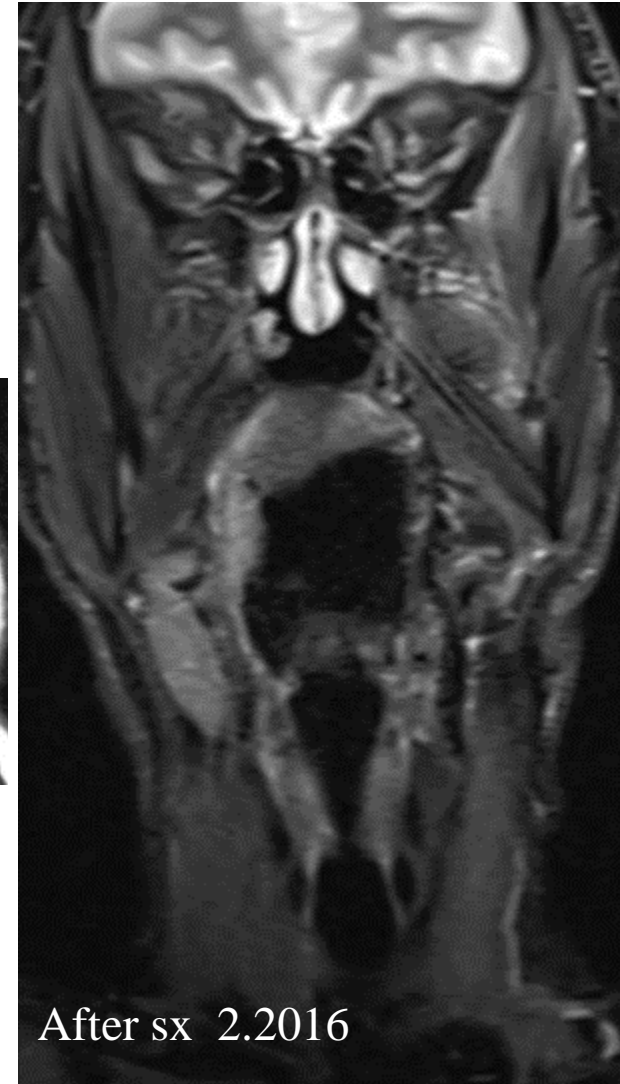
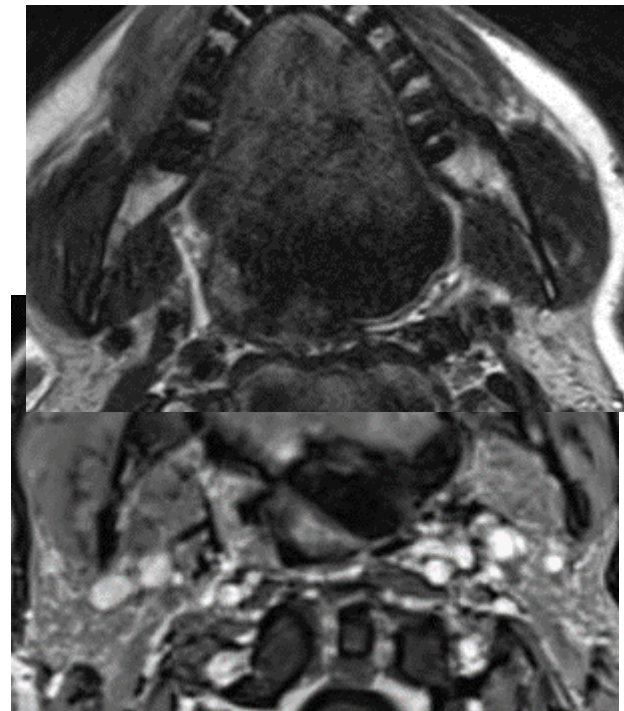
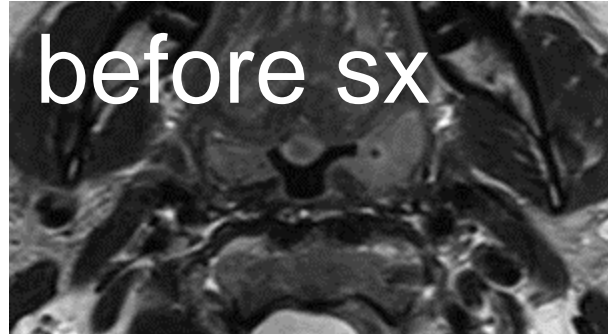
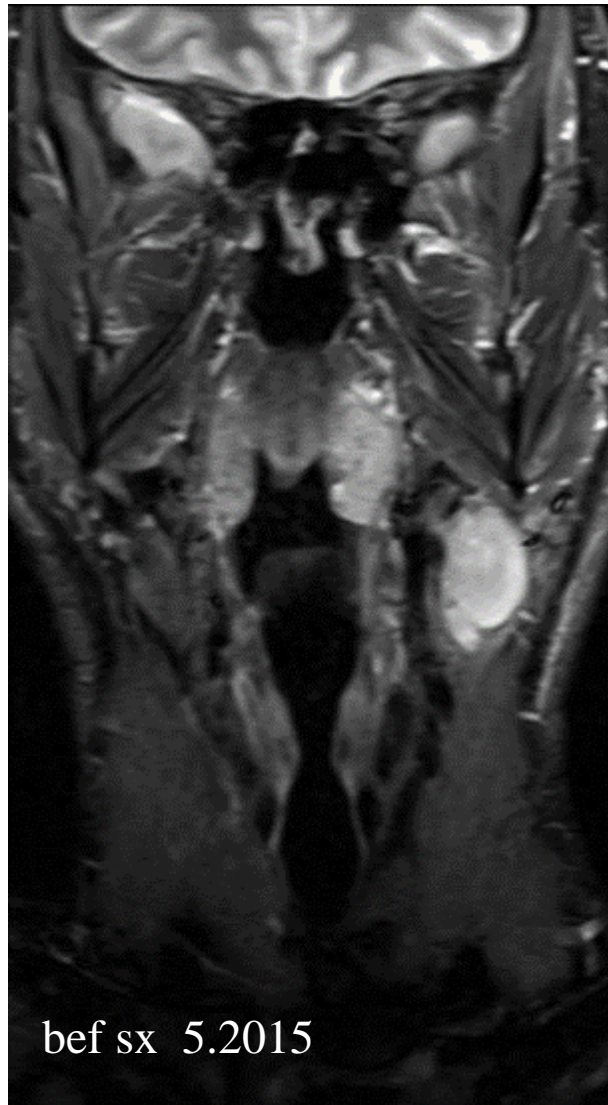


lary ?

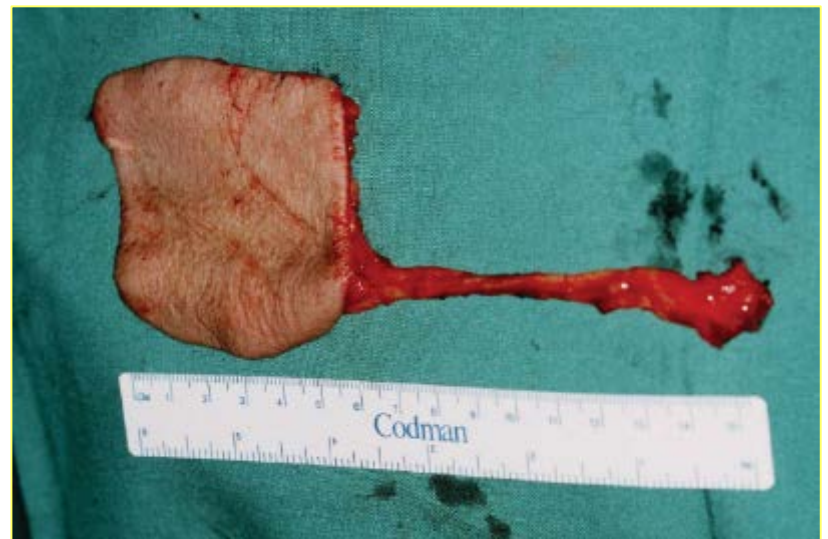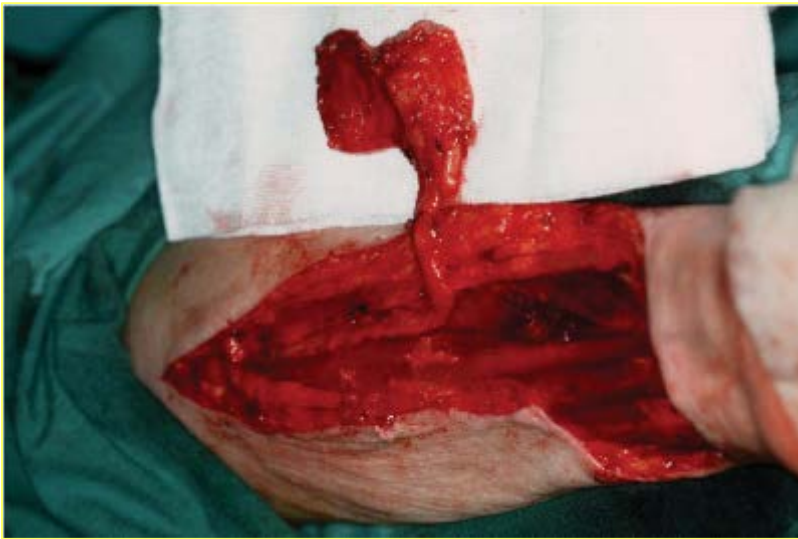
tonsillar-ca



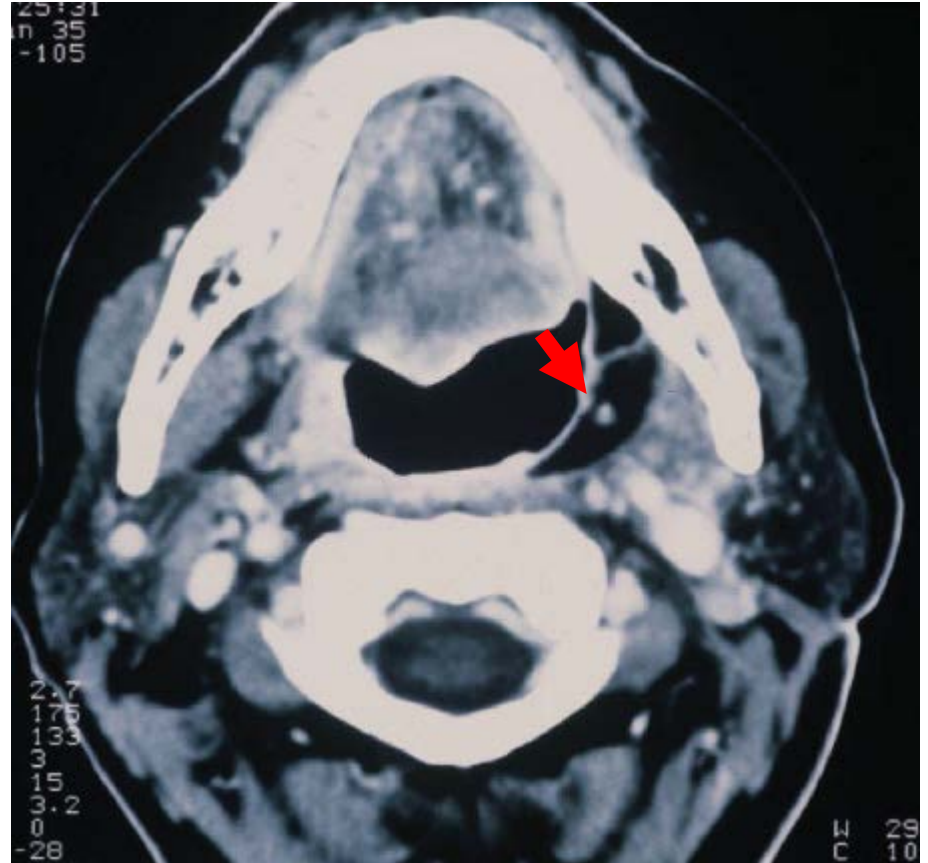
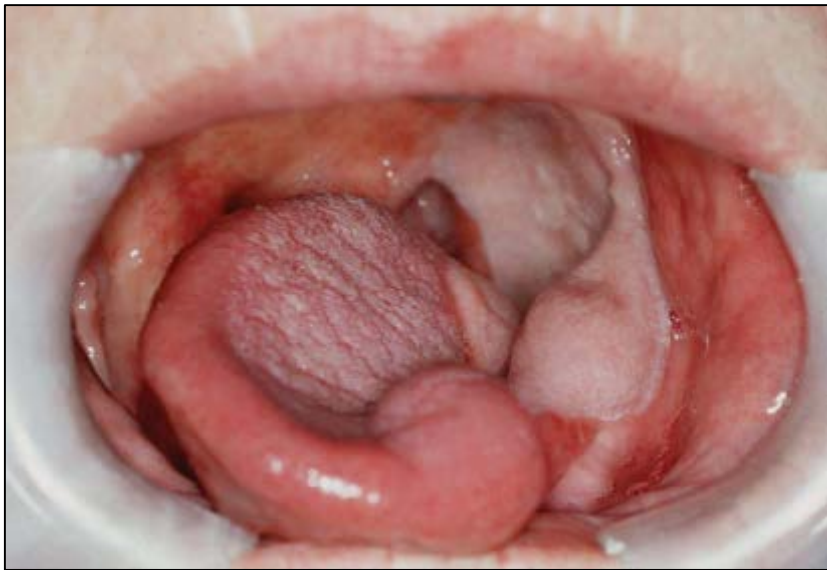transoral tu resection, RFFF and ND I-IV left

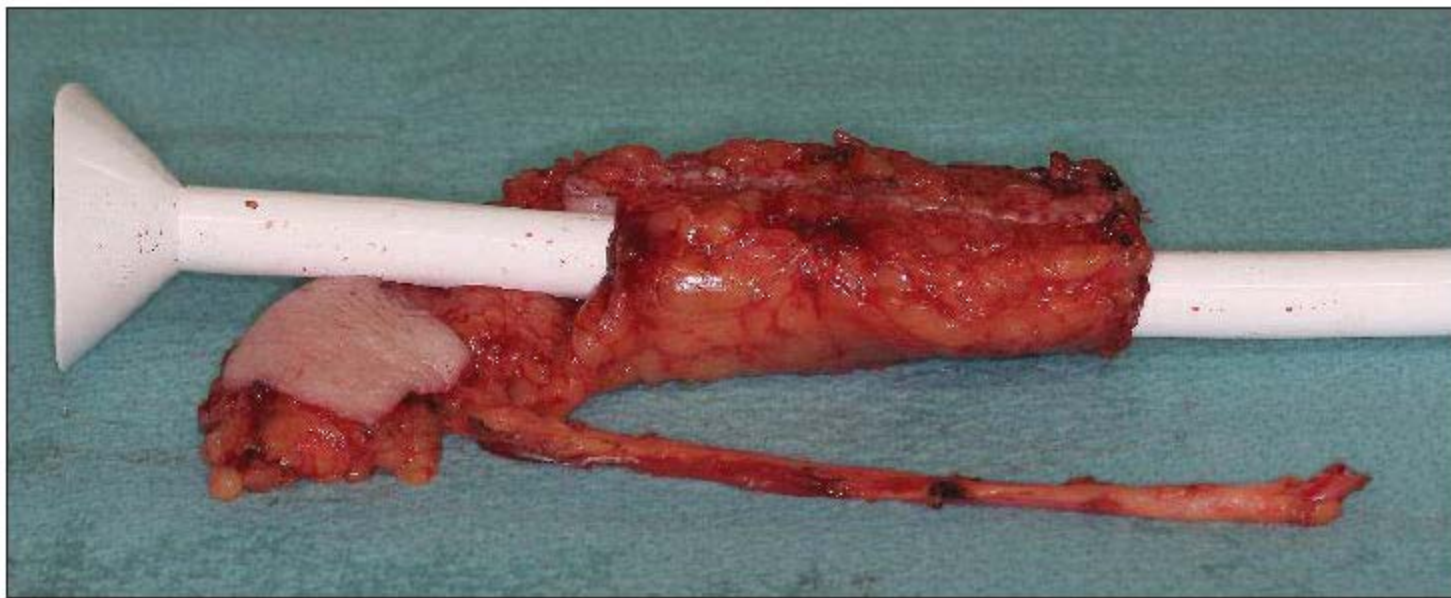
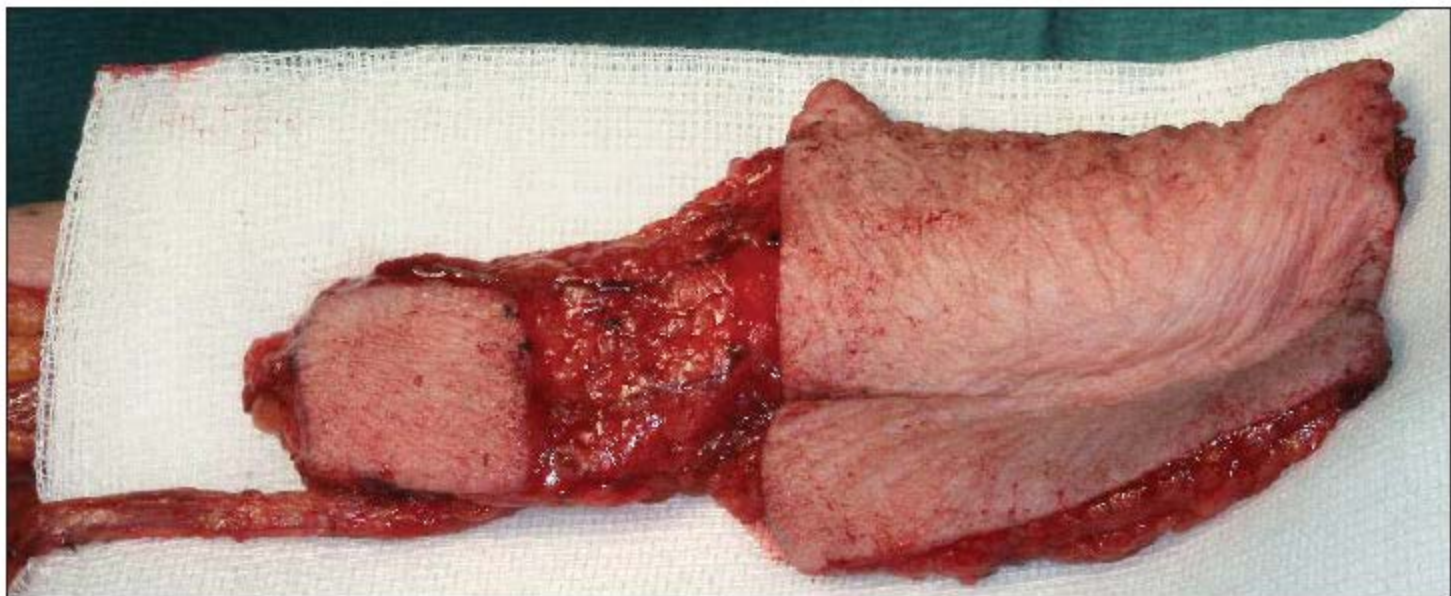


changed anatomy after sx with flap
reconstruction



changed anatomy after sx with flap reconstruction



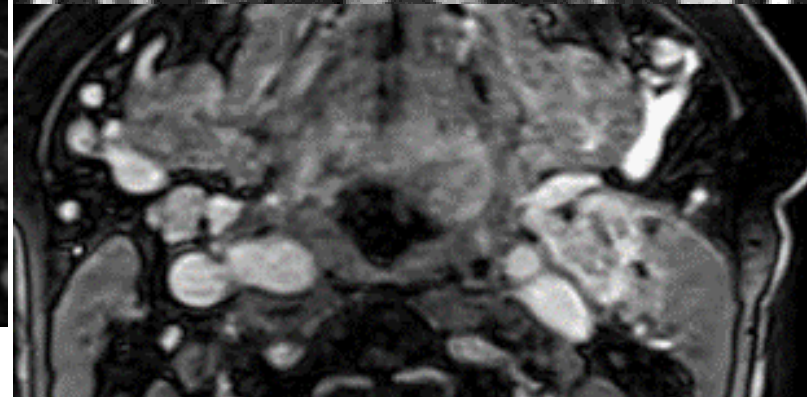
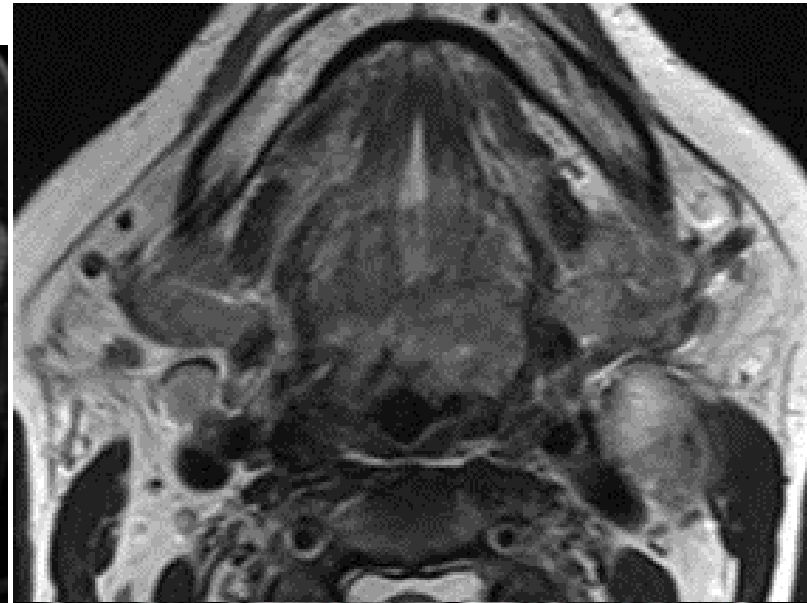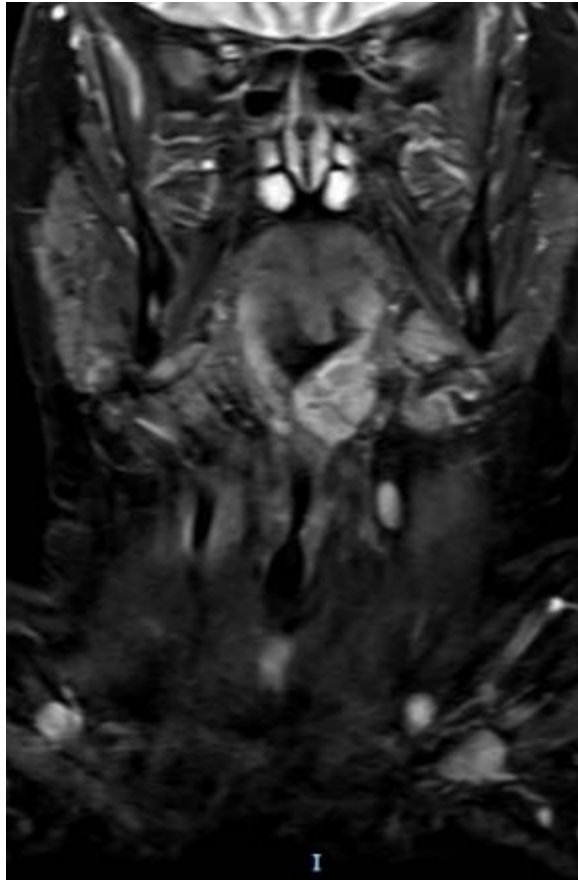

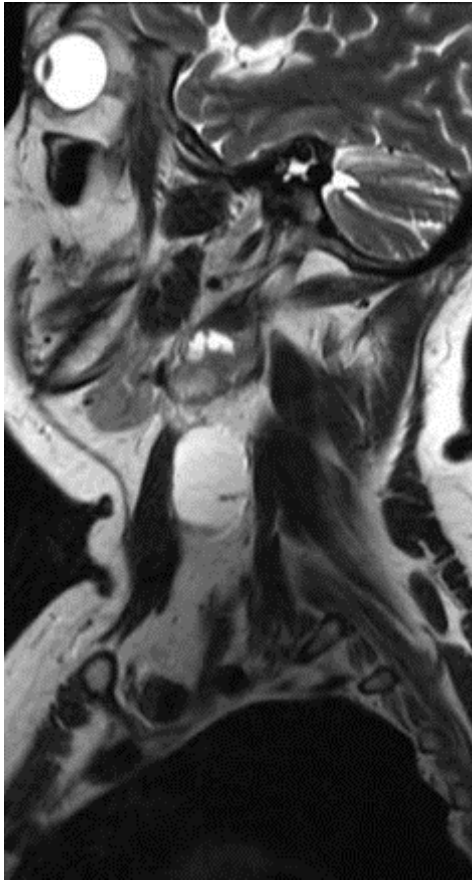
staging carcinomas of mesopharynx and oral cavity

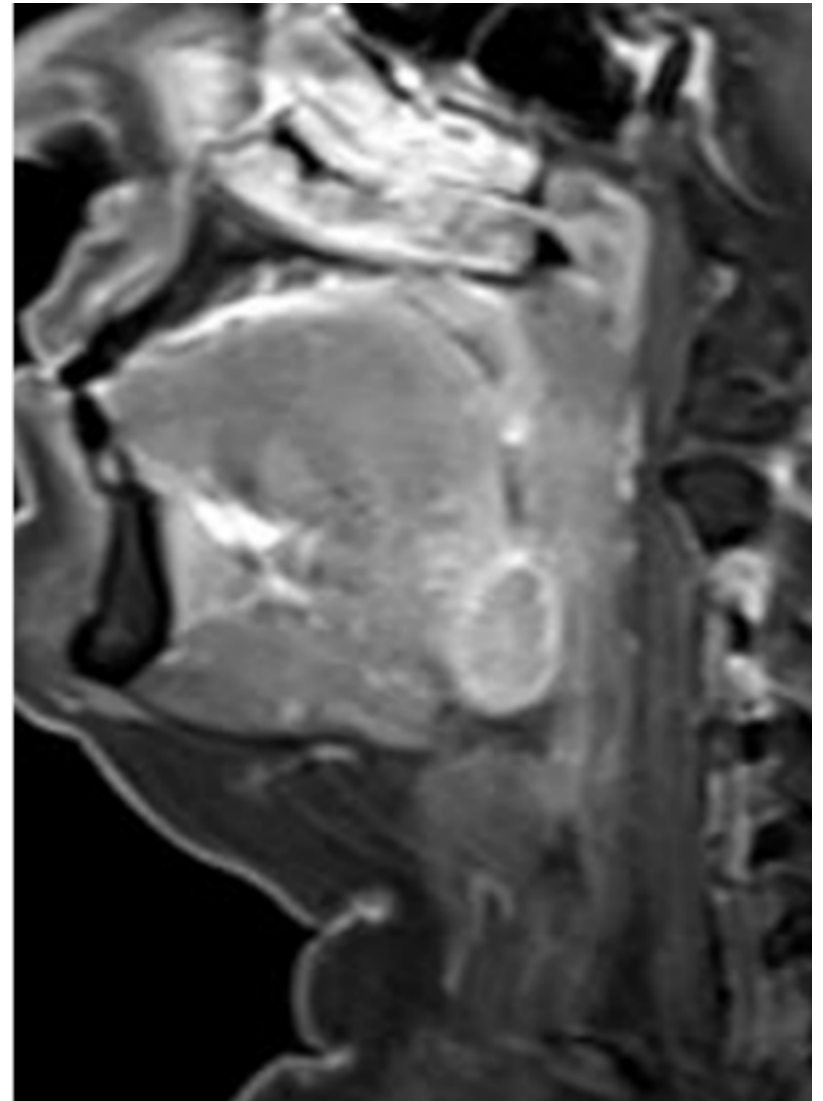
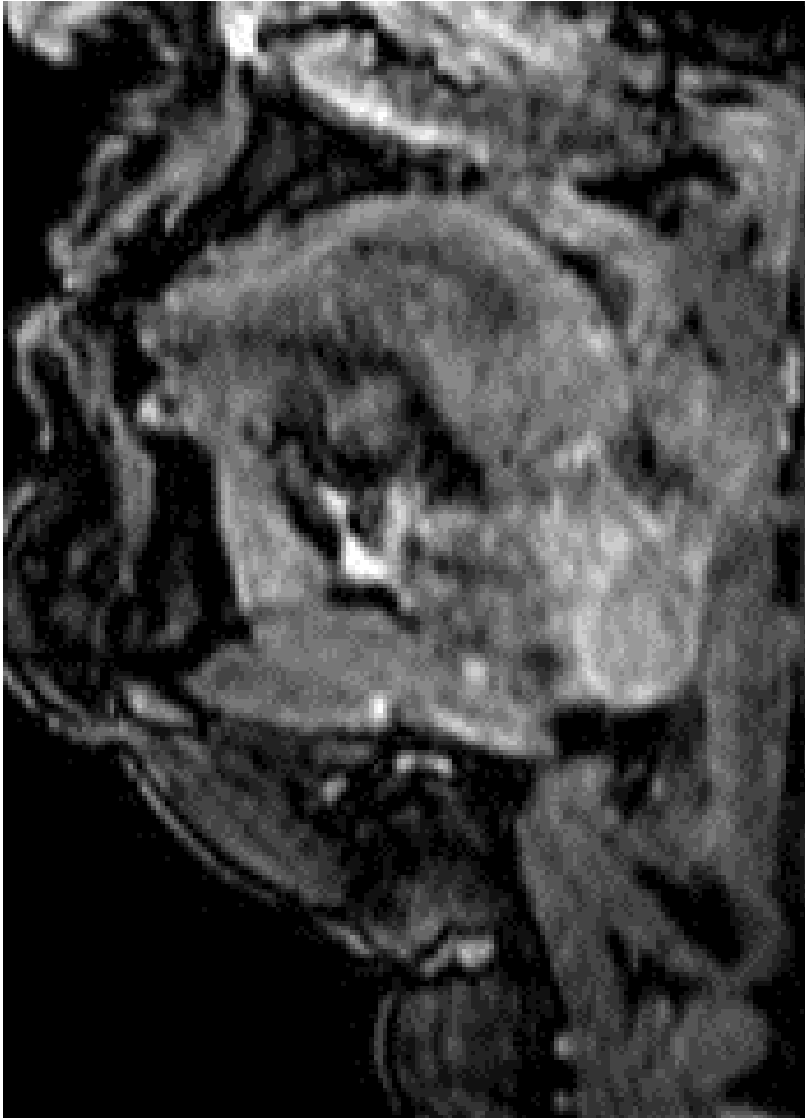- **T1 Tu \leq 2cm maximal extension**
- **T2 Tu $>$ 2cm \leq 4cm maximal extension**
- **T3 Tu $>$ 4cm maximal extension**
- **T4a Tu infiltrating supragl. larynx, extrinsic musc.,
potentially resectable**
- **T4b Tu infiltrating masticator space, skull base, ICA**

strategy of investigation: **3 planes**

1. **sag** T2, 2. **cor** STIR, 3. **ax**: T2, T1 \pm Gd,

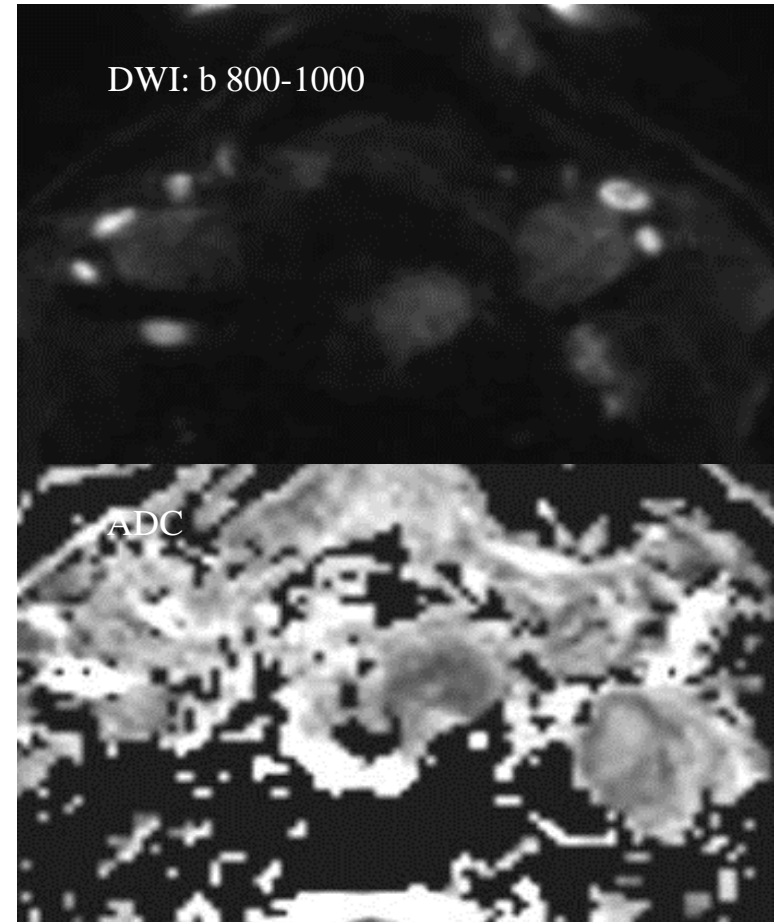
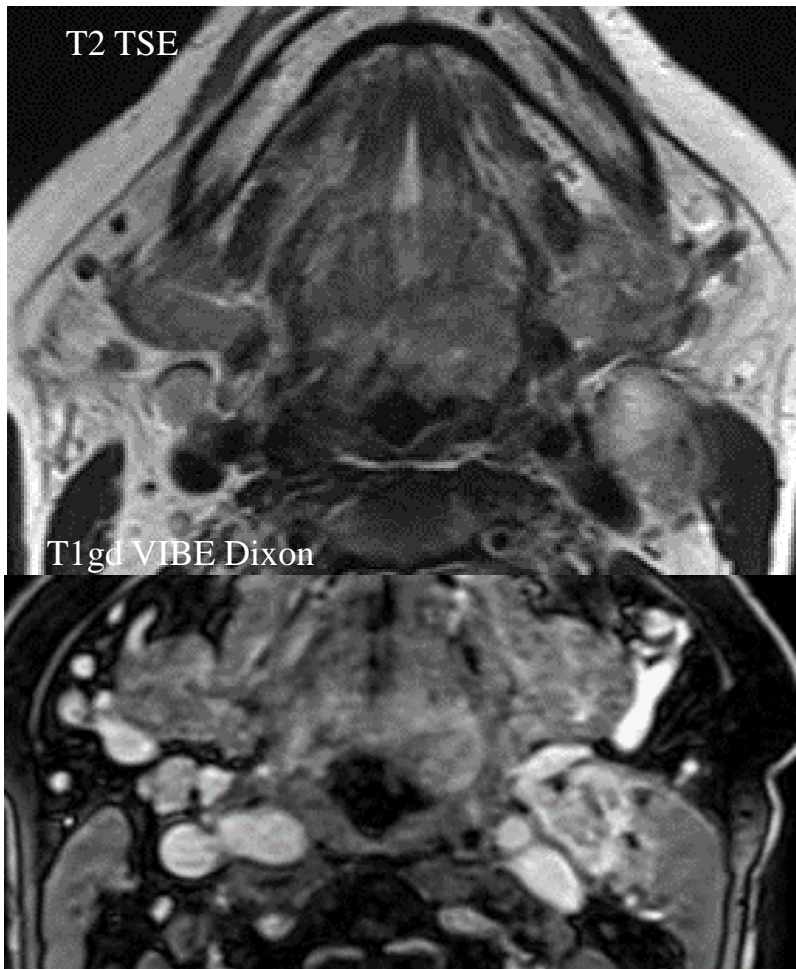


images after i.v. contrast dye **early - late**



morphology and DWI

HPV + Mesopharynx ca



“pN value > 5 for oropharyngeal cancers was associated with decreased survival”
Roberts T et al. Cancer 2016; 122:1388–1397

HPV + oropharyngeal Karzinome

HPV+ und HPV- Ca = different tumour entities

histology:

HPV+ : non-keratinizing, ∞ mitotic fig. + necrosis

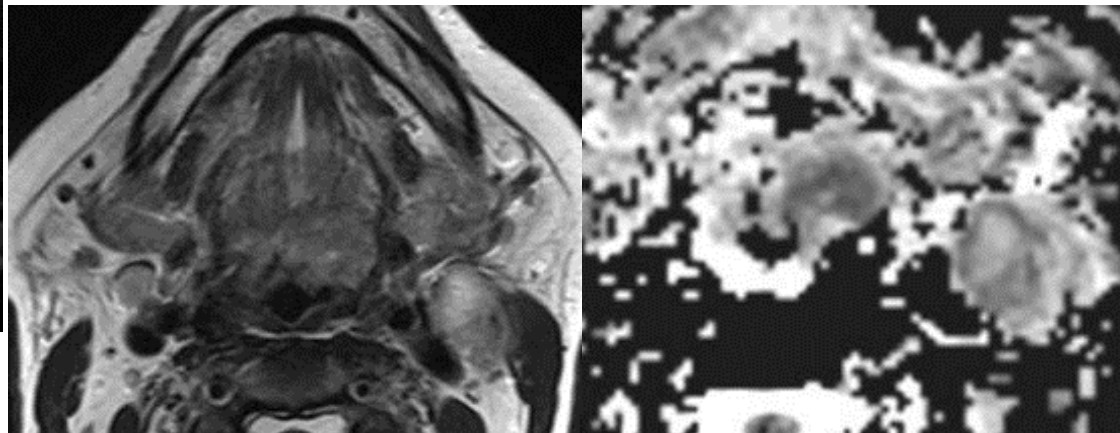
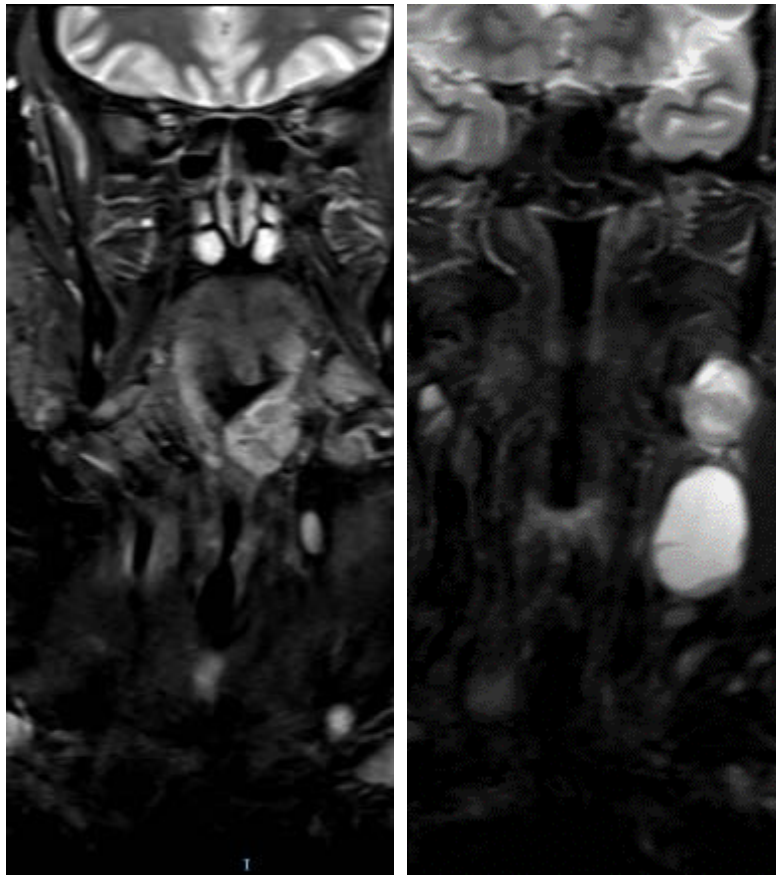
HPV - : large polygonal keratinizing cells

imaging:

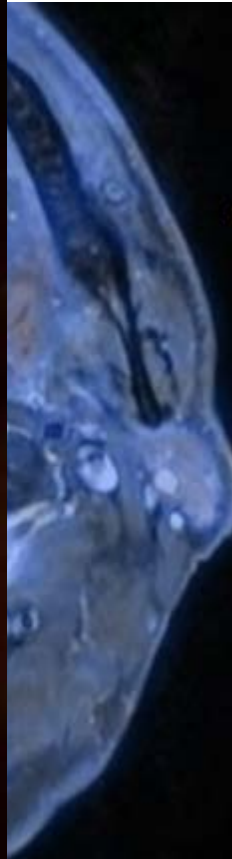
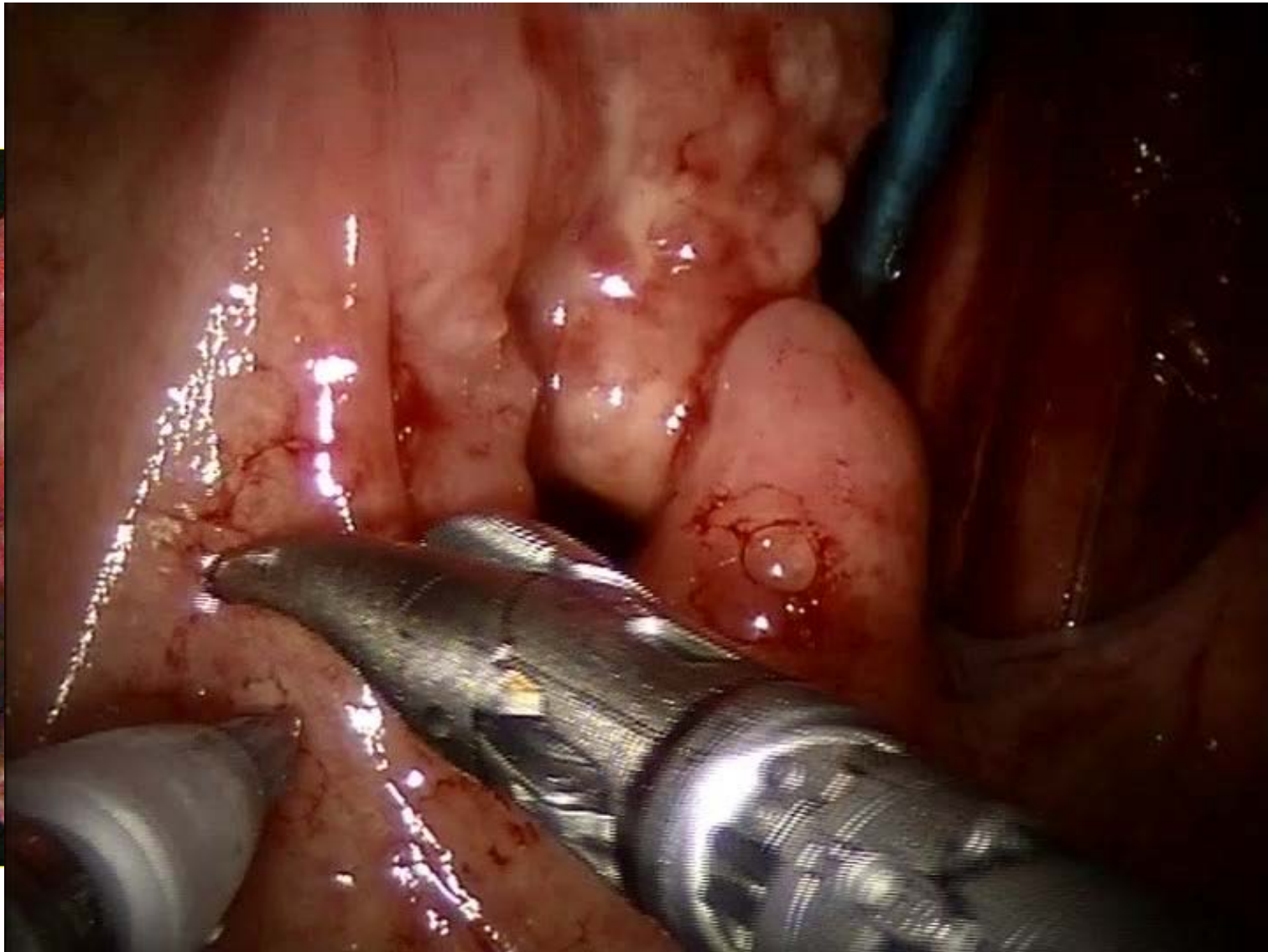
HPV+ : exophytic, KD \uparrow + clearly delineated, frequent cystic metastatic lymph nodes (36%)

HPV - : infiltrating, KD +/-, blurred delineation, cystic in rare (9%)

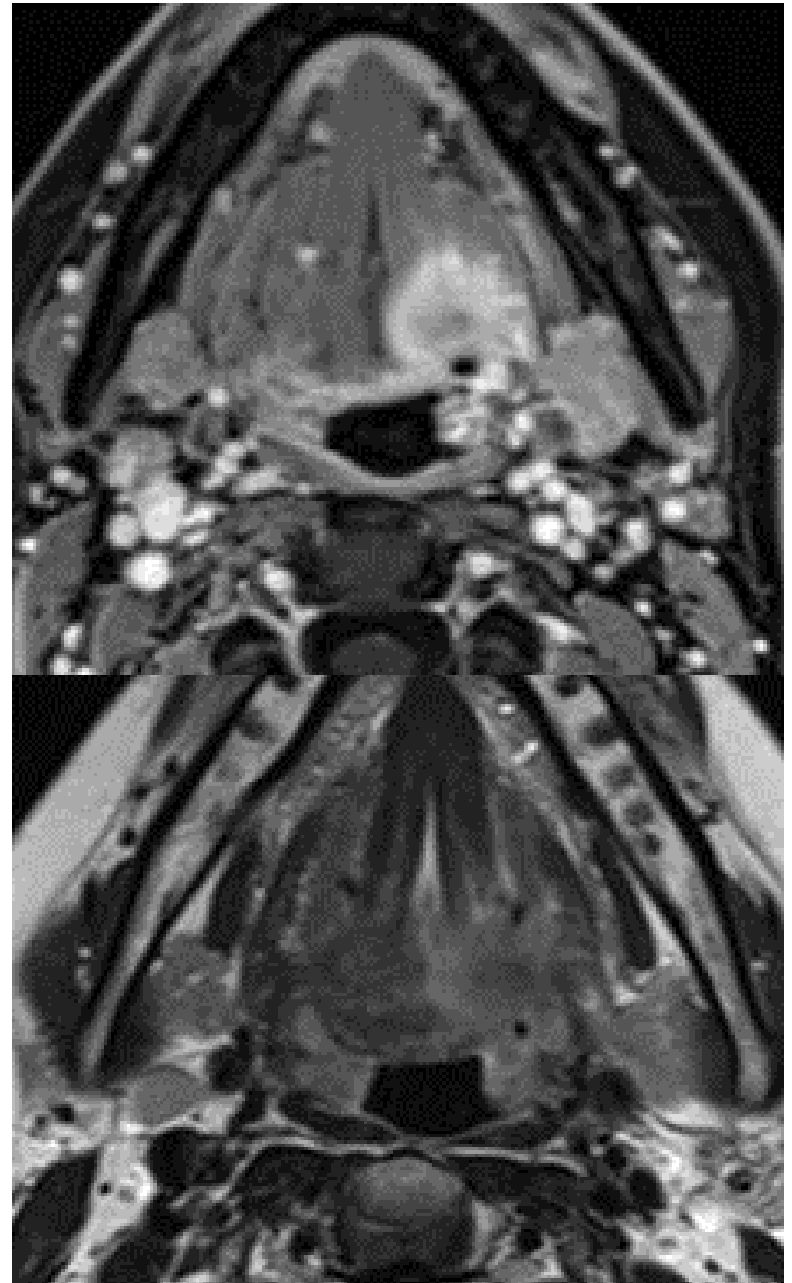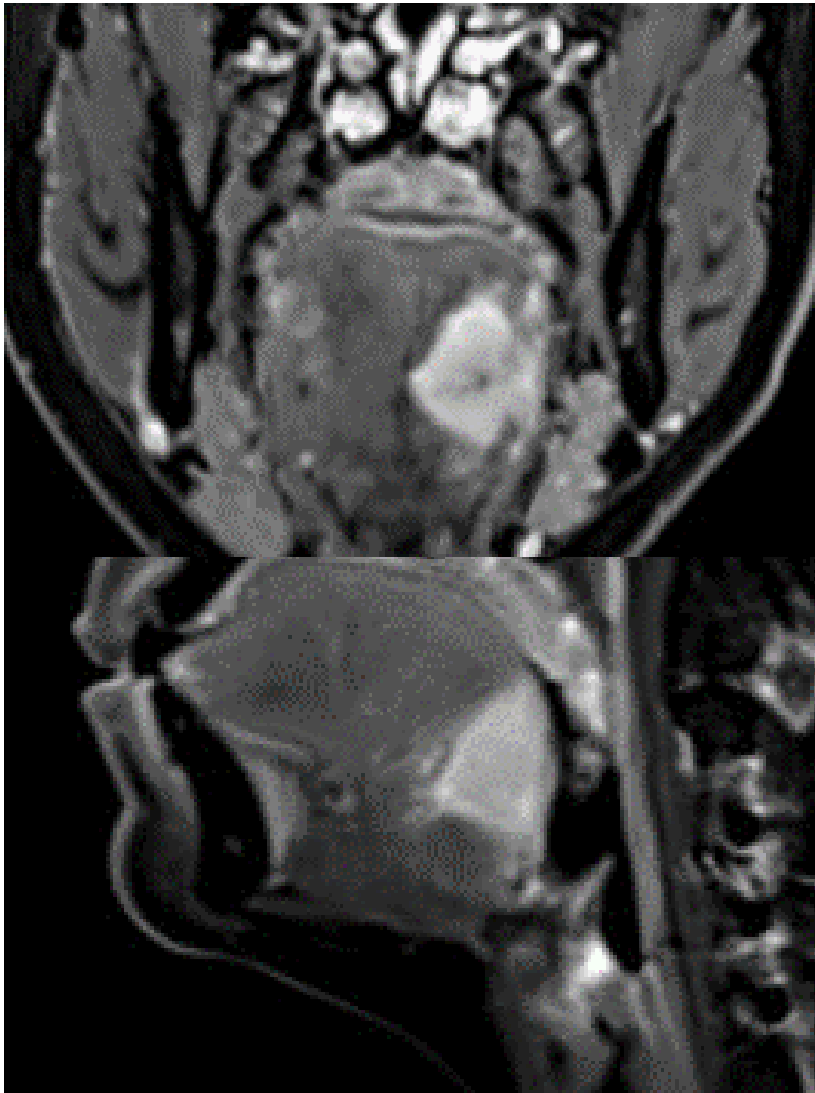
HPV+ : Tendenz zu \downarrow ADC in solid portion



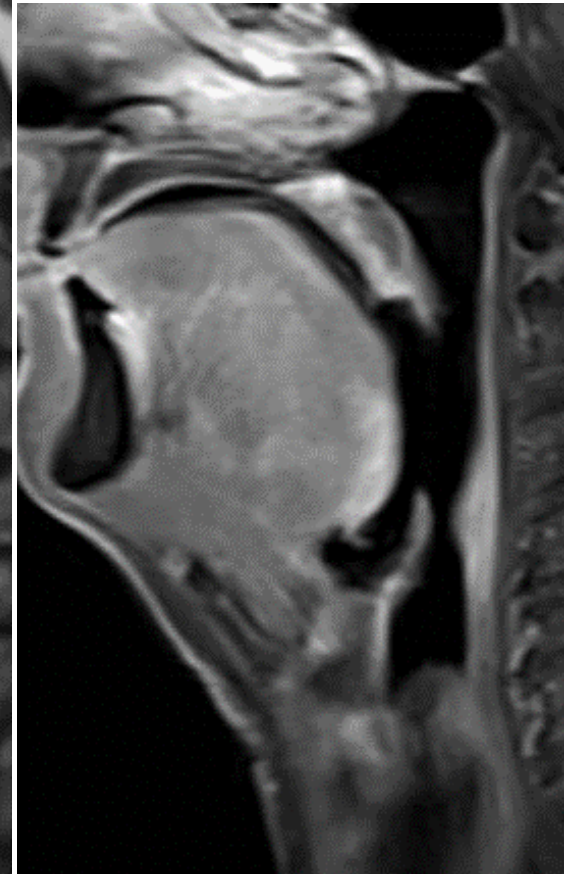
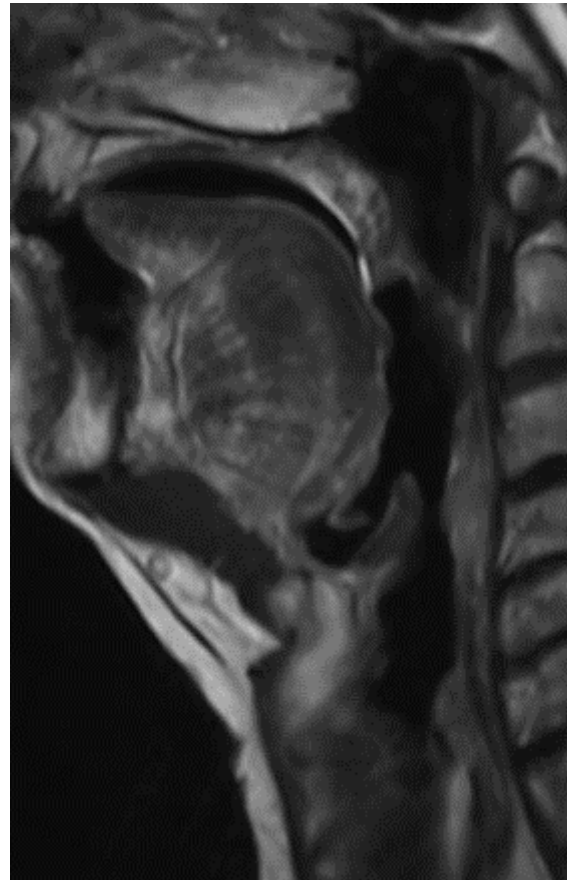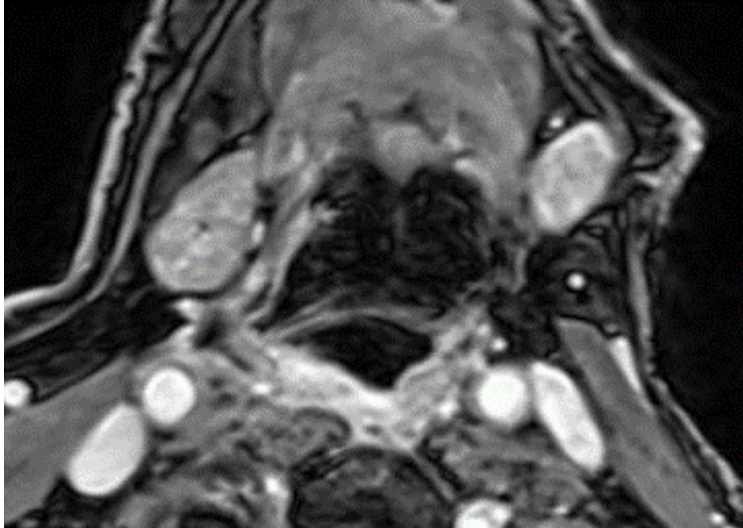
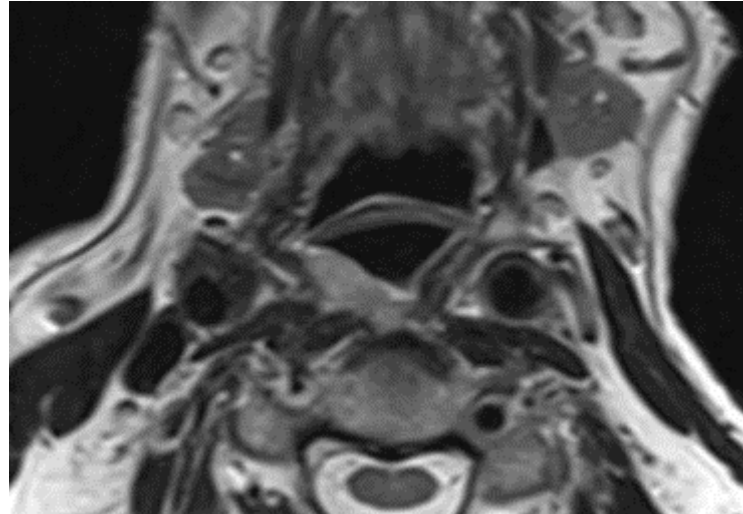
TORS of HPV+ tumour



50y f smoking & drinking
p16 neg

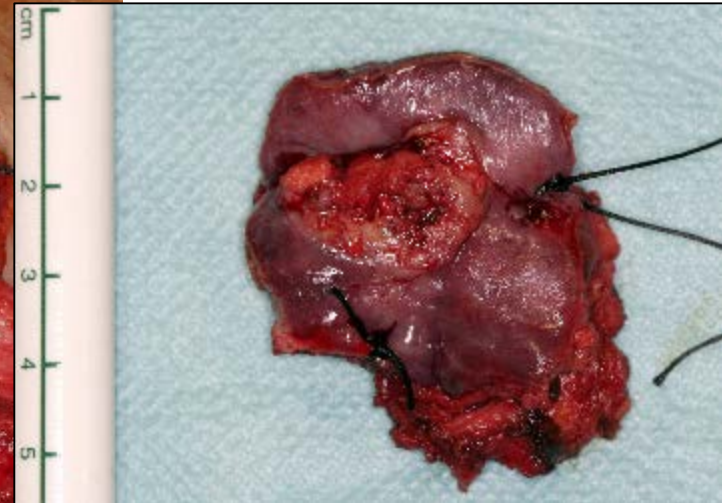
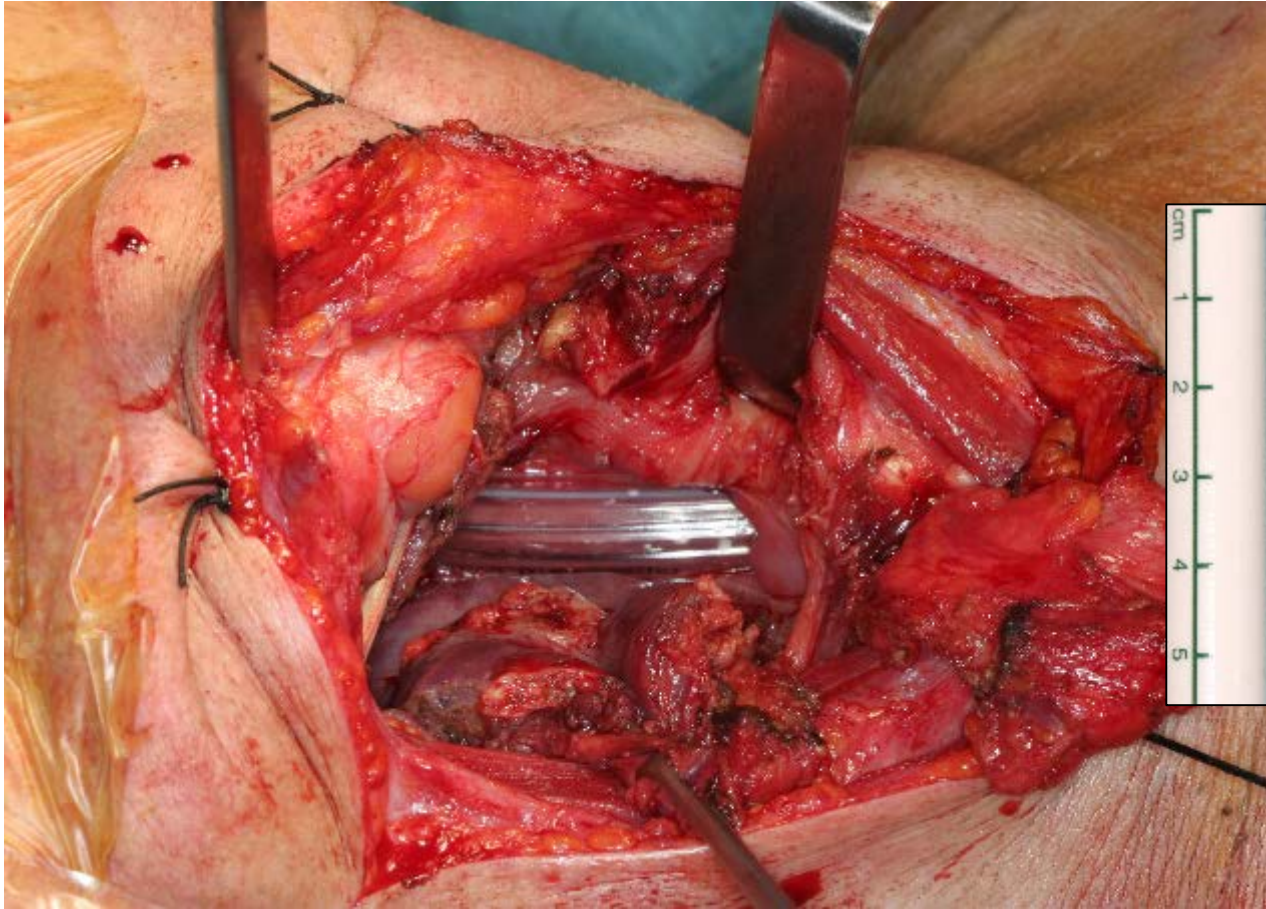


posterior pharyngeal wall

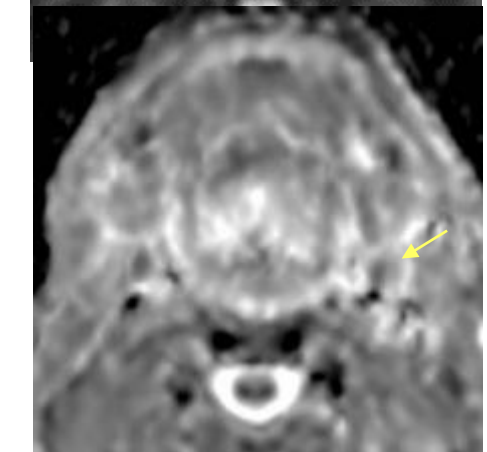
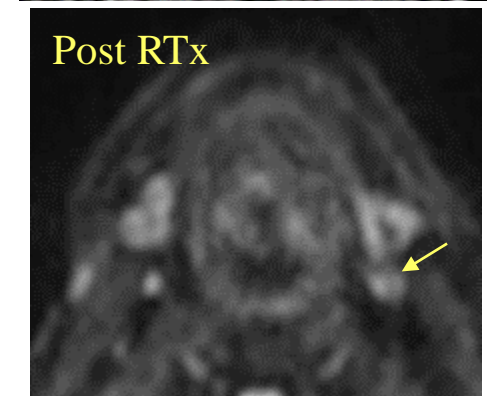
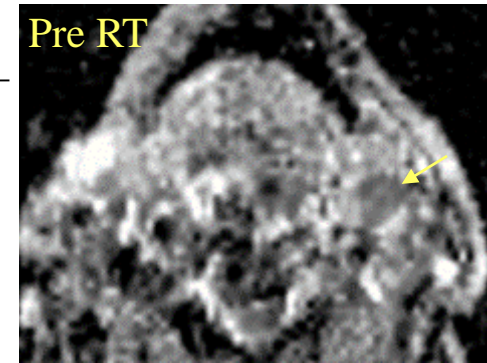
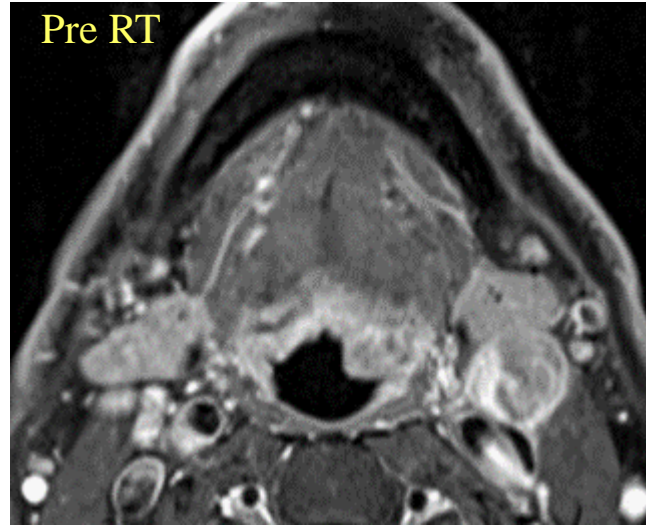
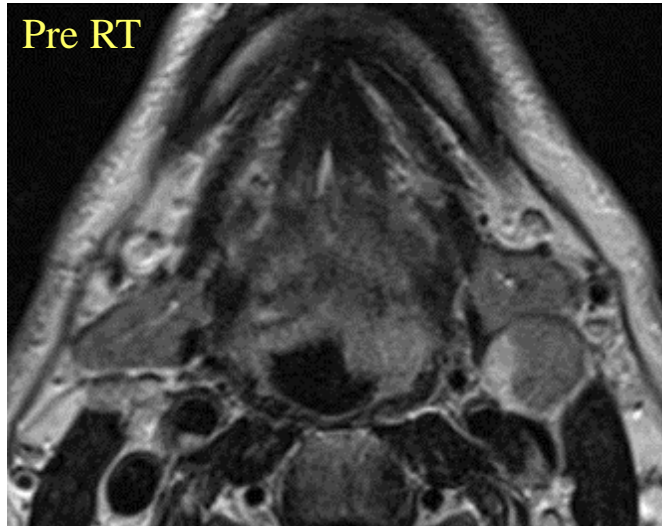


involvement of prevertebral fascia?

posterior pharyngeal wall



Primary – LN metastasis?



indication for salvage ND because of persisting nodal disease

nodal disease: MR + CT criteria

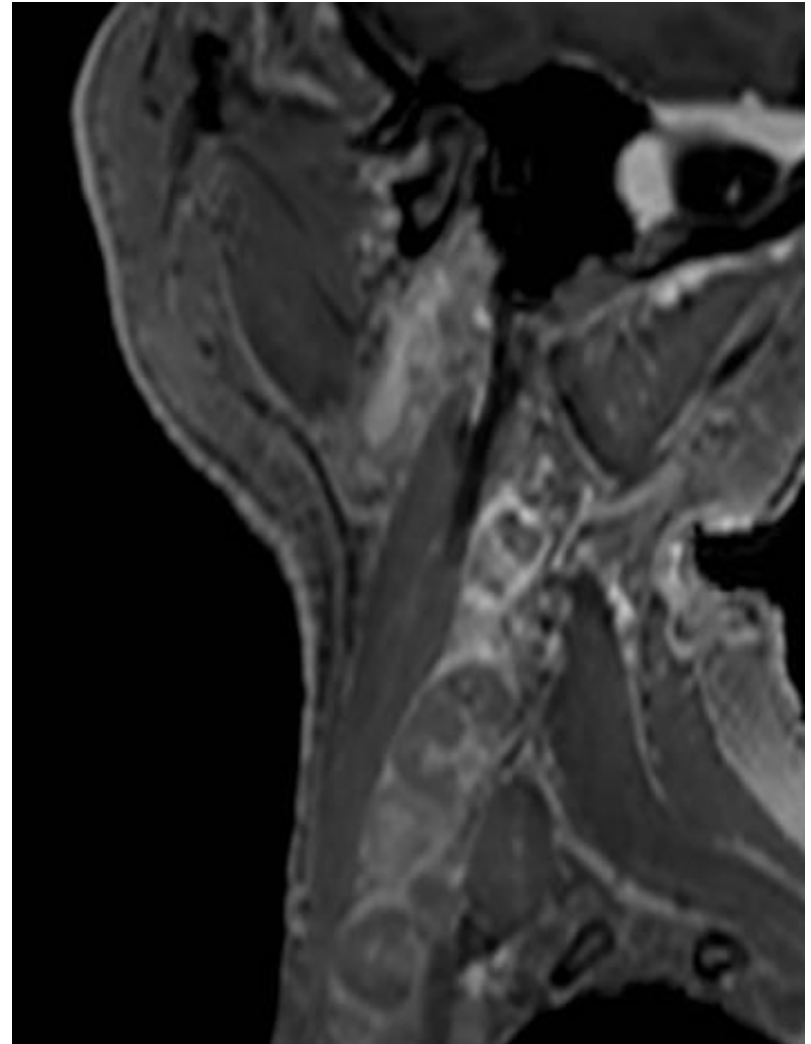
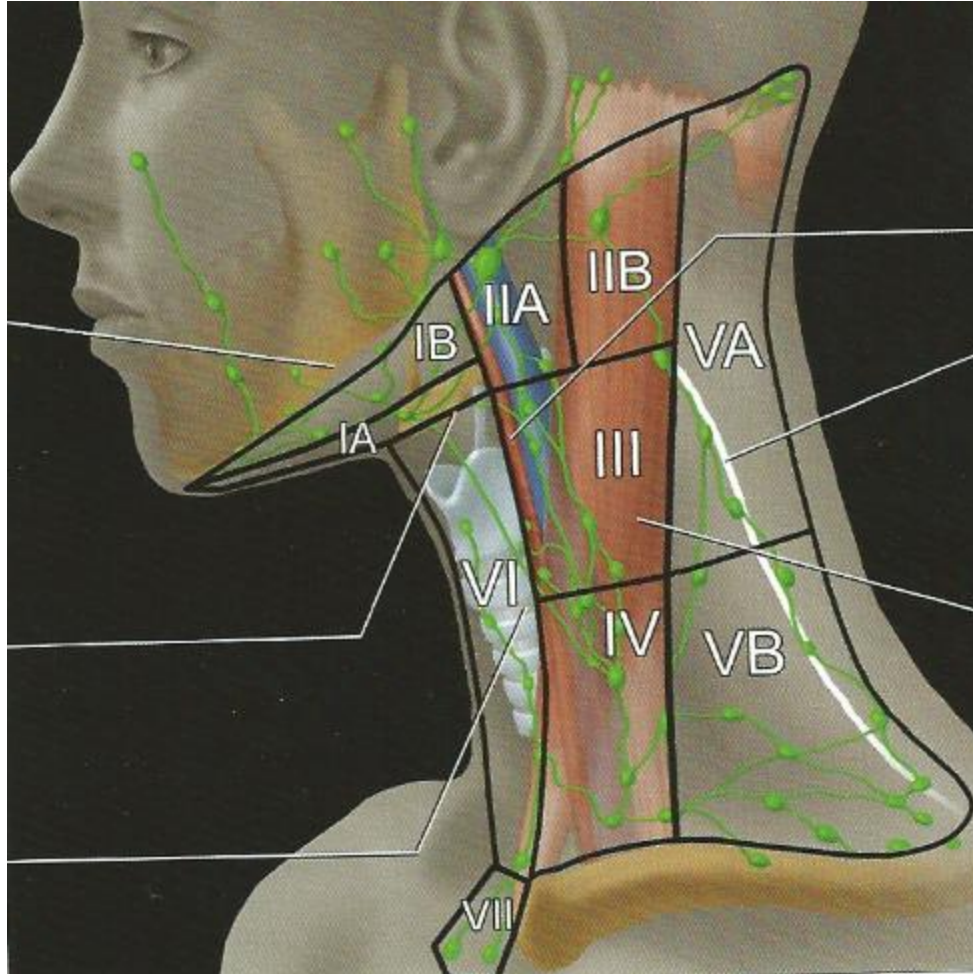
- > 10mm diameter of short axis
- > 8 mm transversal diameter of retropharyngeal nodes
- round shape (supporting criterion if size marginal)
- In of all sizes with central hypodensity, hypointensity
- Conglomerate of 3 or more marginally enlarged In
- diffuse delineation of surrounding tissue around enlarged In
- *„size is the least reliable among the criteria listed“*

Som PM. Detection of metastasis in cervical lymph nodes: CT and MR criteria and differential diagnosis. *AJR Am J Roentgenol* 1992; 58:961–969

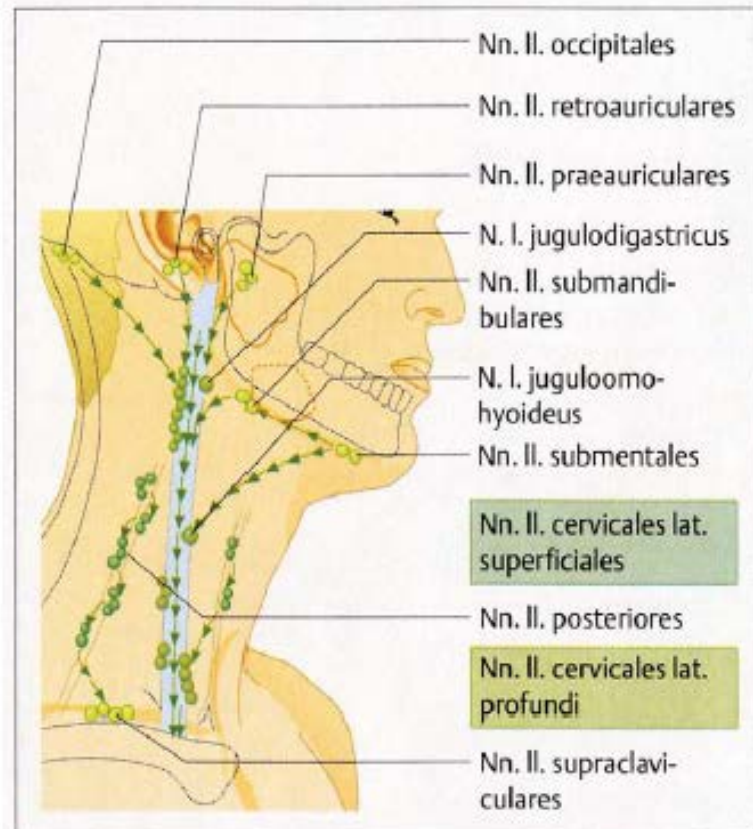
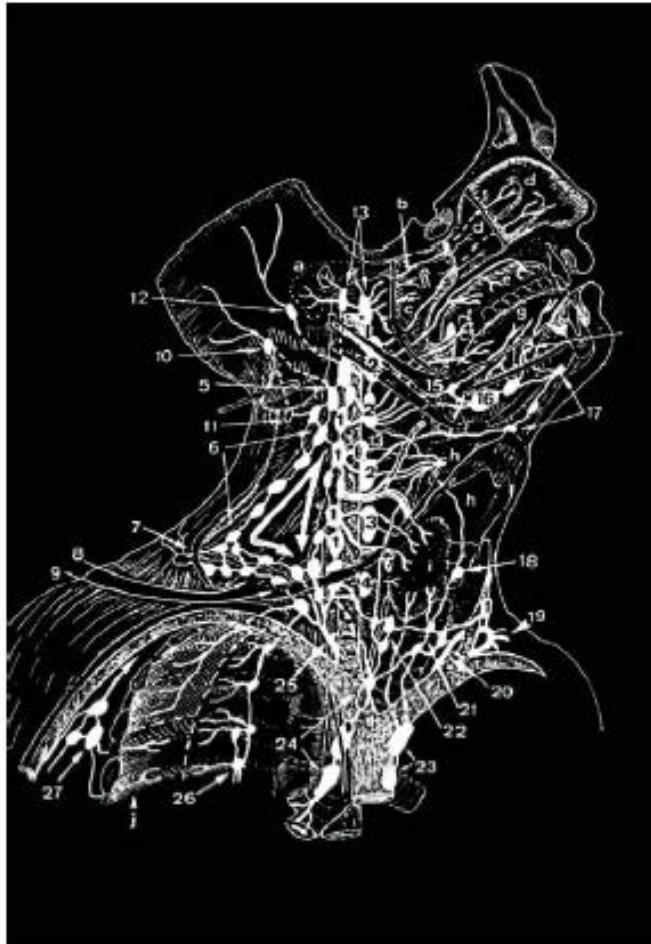
LN Staging

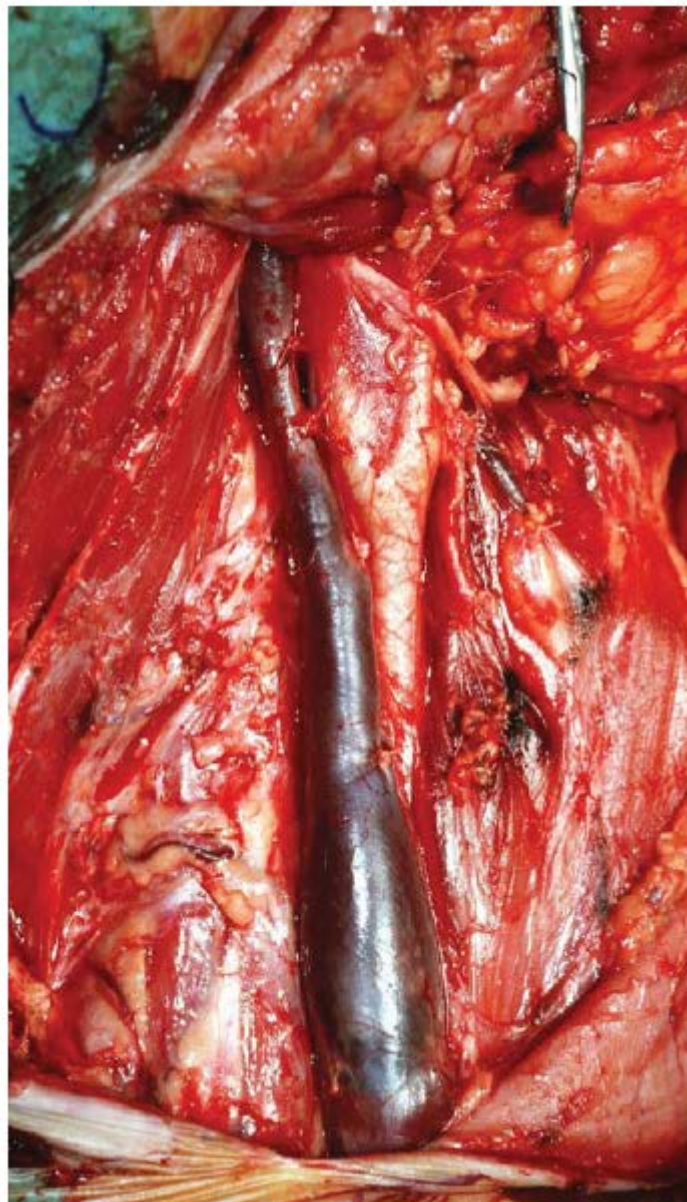
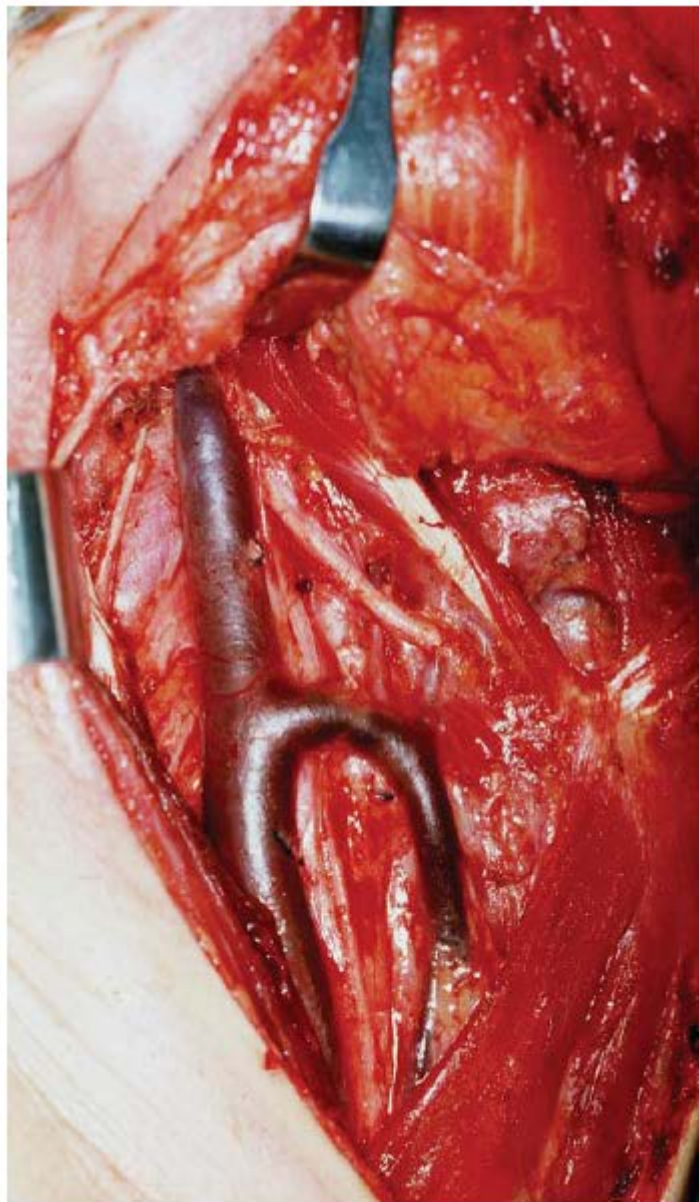
- **N0** no regional LN metastasis
- **N1** singular ipsilateral LN $\leq 3\text{cm}$
- **N2a** singular ipsilateral LN $> 3\text{cm} < 6\text{cm}$
- **N2b** multiple ipsilateral LN $< 6\text{cm}$
- **N2c** bilateral or kontralateral LN $< 6\text{cm}$
- **N3** LN Metastasis $> 6\text{cm}$

LN levels

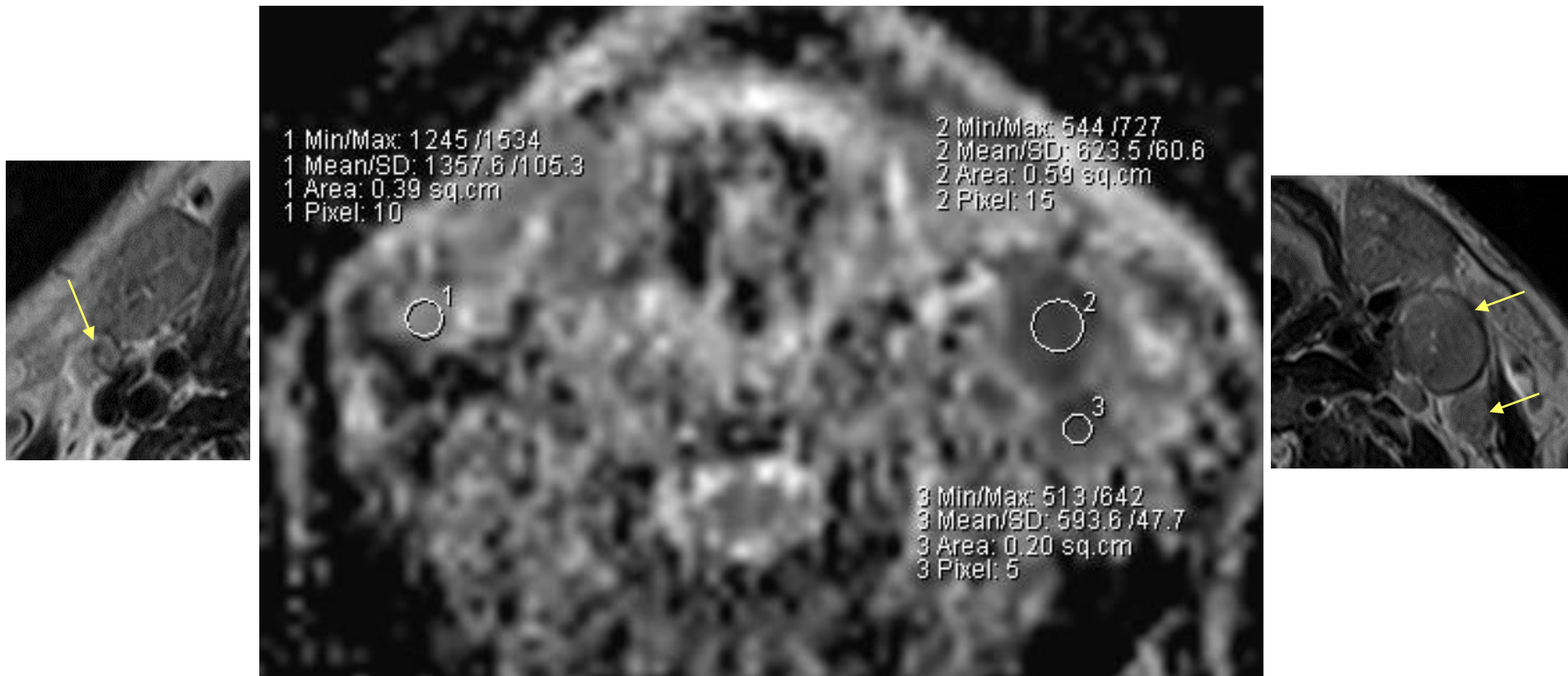


LK levels



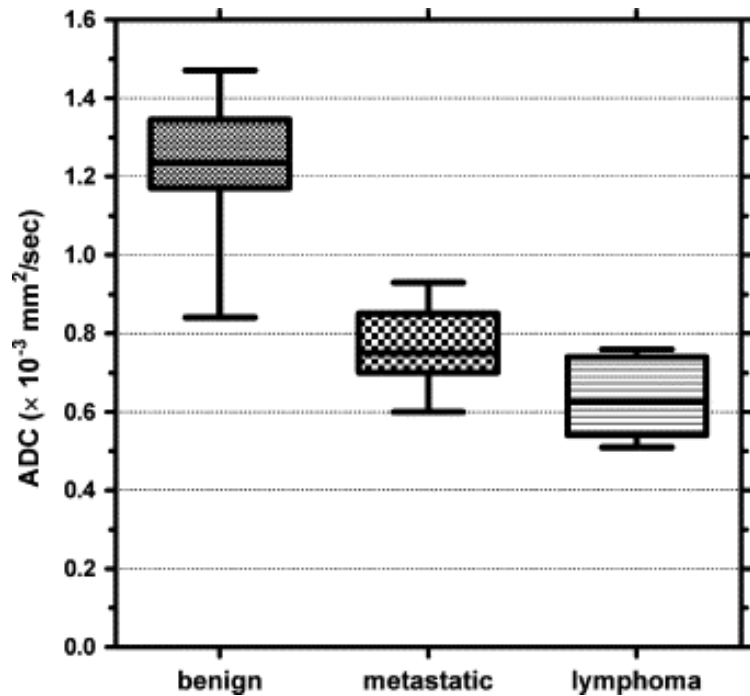


quantifying ADC values



the mean value of benign nodes $1.448 \times 10^{-3} \text{ mm}^2/\text{s}$;
the mean ADC value of malignant nodes $0.85 \times 10^{-3} \text{ mm}^2/\text{s}$,
best threshold value was $1.03 \times 10^{-3} \text{ mm}^2/\text{s}$, (sensitivity 100%, specificity of 92.9%).
Perrone A et al. European Journal of Radiology 2011; 77: 281-286

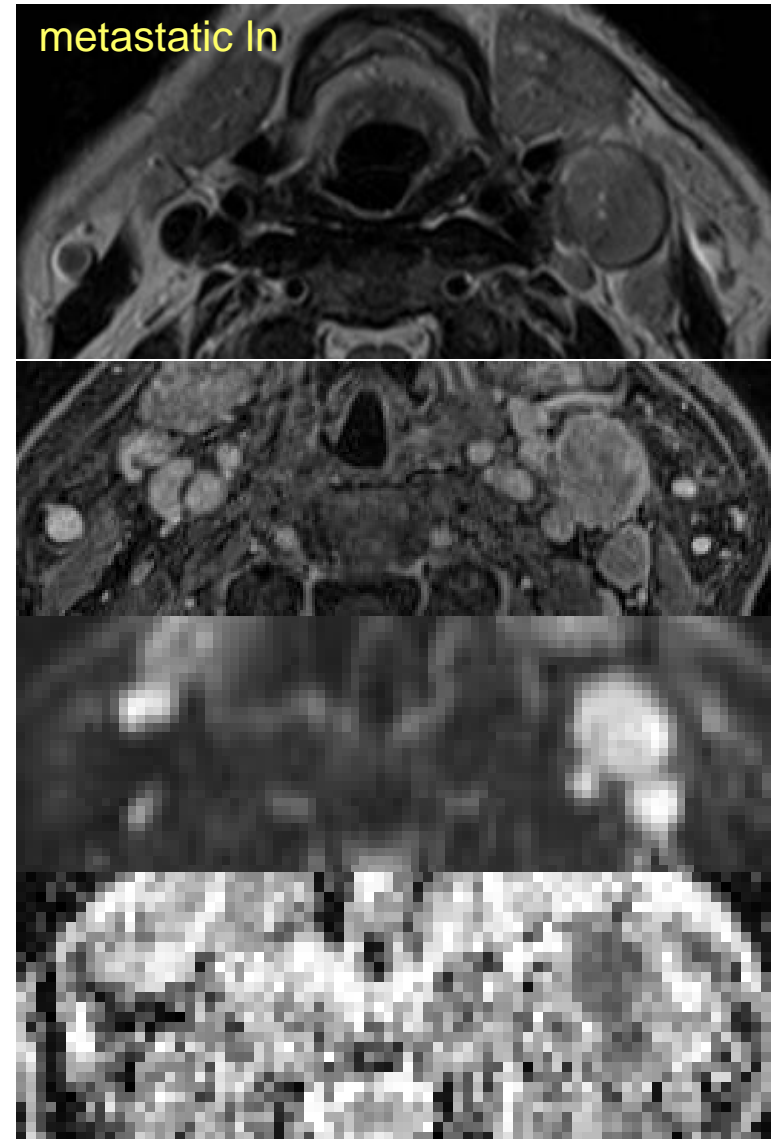
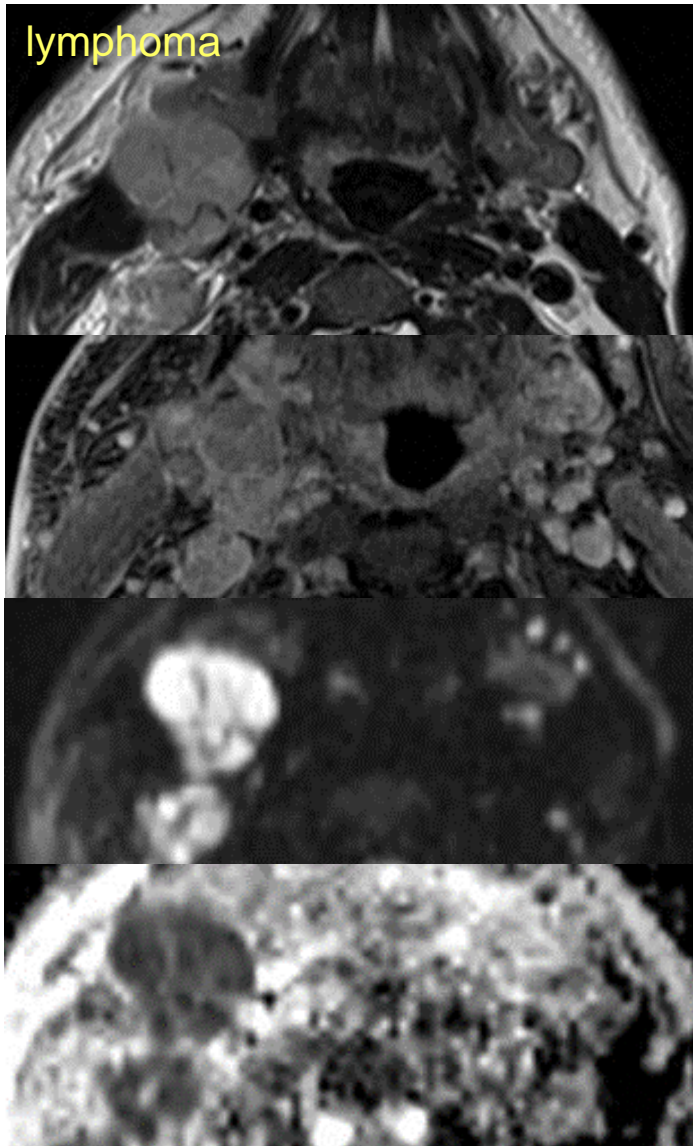
ADC threshold value for differentiating between benign and malignant cervical In $1.02 \times 10^{-3} \text{ mm}^2/\text{s}$.



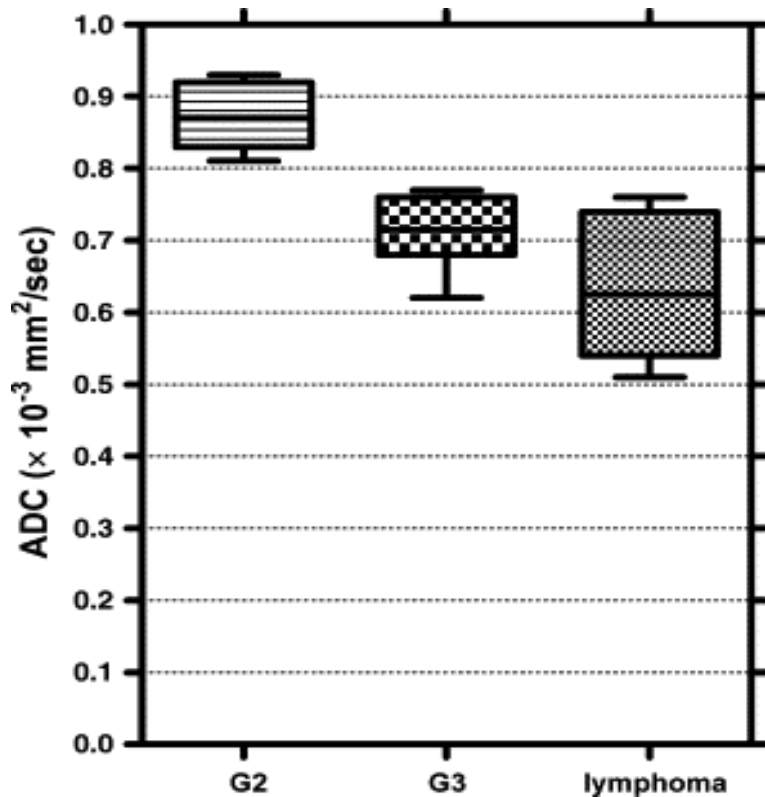
sensitivity	100%,
specificity	87.0%,
accuracy	94.3%,
PPV	90.9%
NPV	100%.

Holzapfel K et al. Value of diffusion-weighted MR imaging in the differentiation between benign and malignant cervical lymph nodes Eur J Radiol 2009; 72:381-387

ADC < lymphoma vs metastatic In



ADC ~ histologic grading of metastatic In



“ADC values of metastatic moderately (G2) & poorly (G3) differentiated carcinoma and lymphomatous nodes differences of ADC values between the three groups were statistically significant ($P < 0.05$) and ($P < 0.05$)”.

ADC values under treatment

tumour

responders → ADC (<0.79) vs non-responders > 0.79) pre Tx

¹Δ ADC > 14% SE 88%, SP 91% 2w Ch-RT

¹Δ ADC > 25% SE 100%, SP 91% 4w Ch-RT

²Δ ADC > 35% SE 45%, SP 100% 6 w post Tx

³ADC > 1.3×10^{-3} mm²/s SE 94%, SP95% end CH-RT

lymph nodes

¹Δ ADC > 14% SE 80%, SP 89% 2w Ch-RT

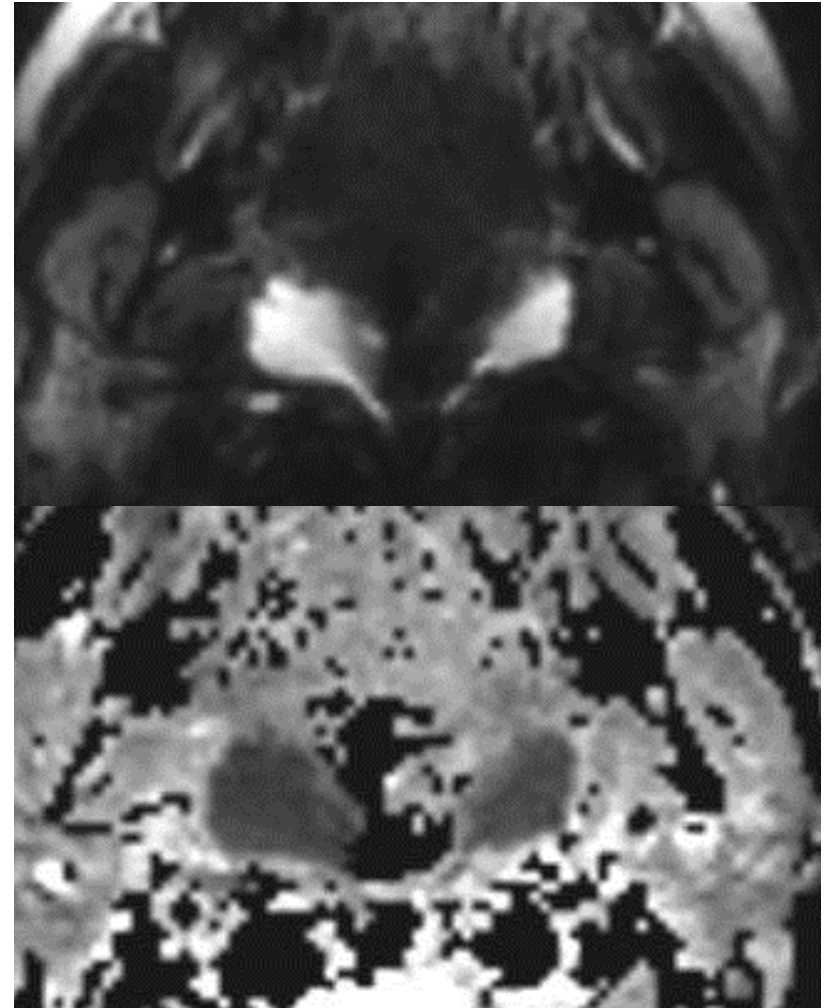
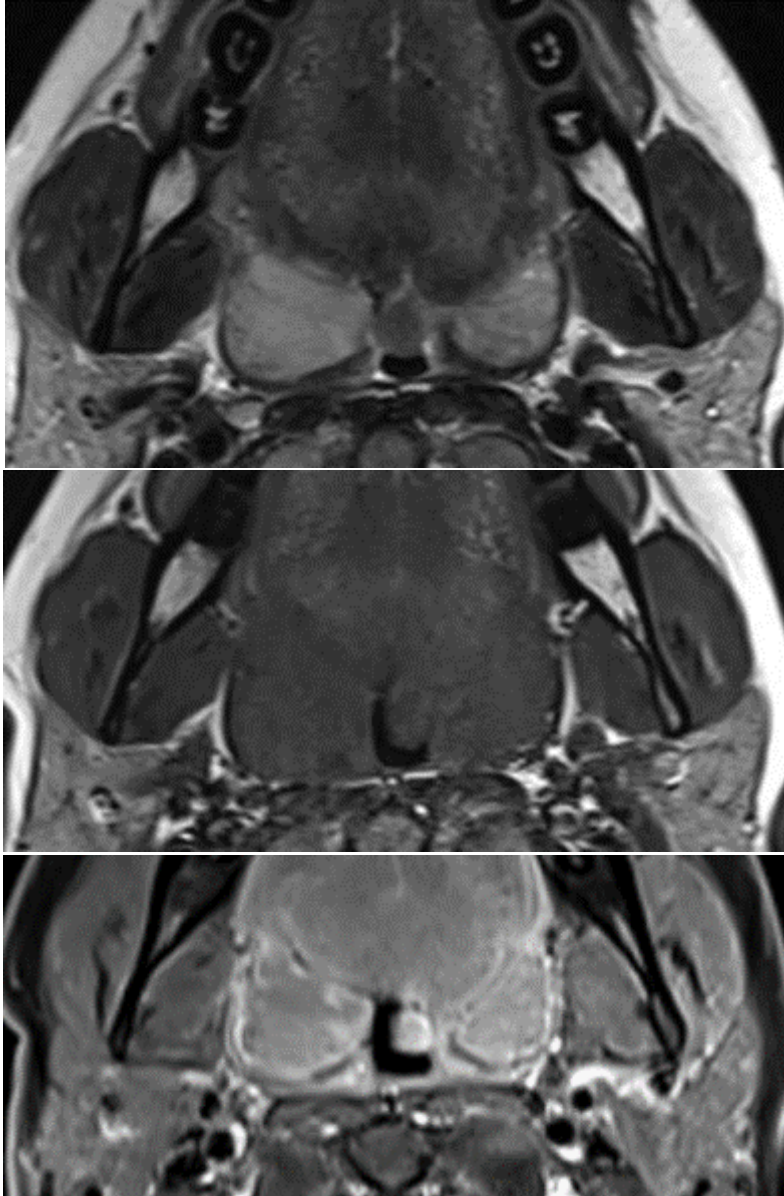
¹Δ ADC > 19% SE 80%, SP 96% 4 w Ch-RT

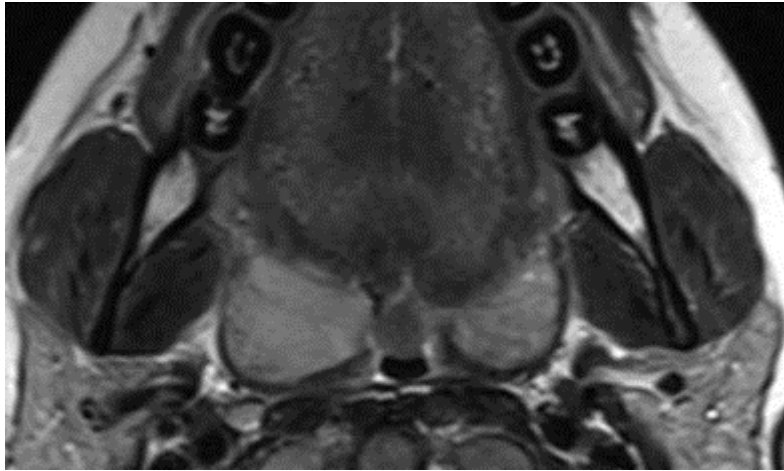
¹ Vandecaveye 2010

² King 2010

³ Vandecaveye 2007

35y, w , Ø risk factors,
foreign body feeling, enlarged tonsil





DCE Perfusion

information regarding micro-vascular structure of neoplasia analyzing kinetics of iv contrast dye bolus

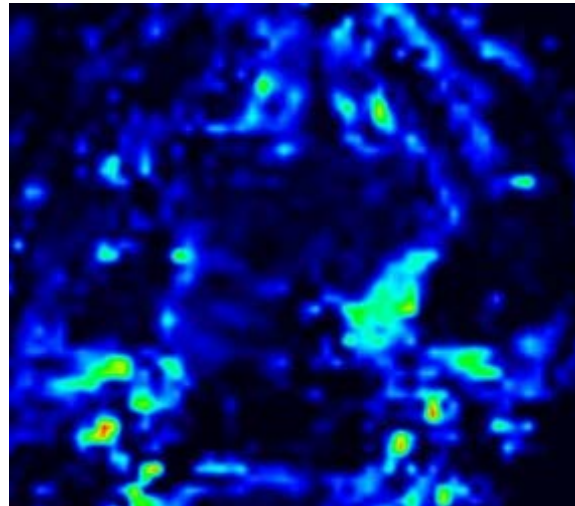
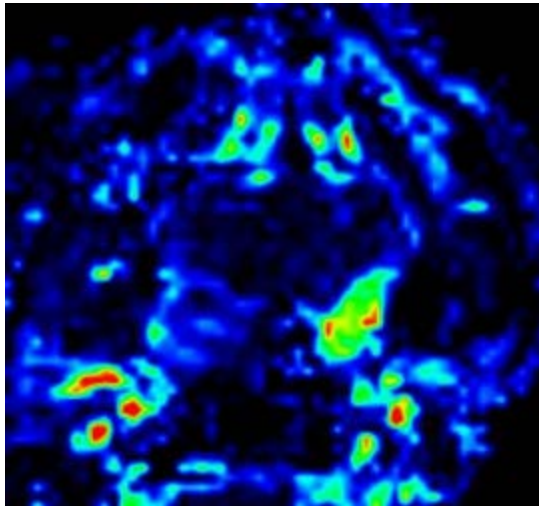


Table 3.

Mean and standard deviation of the DCE parameters for UD, SCC and Lymphoma

	UD	SCC	Lymphoma
Tofts	28	28	8
k_{trans} (1/min)	1.26 ± 0.61	0.78 ± 0.47	0.59 ± 0.18
v_e	0.65 ± 0.16	0.64 ± 0.13	0.54 ± 0.17
v_p	0.11 ± 0.12	0.08 ± 0.06	0.07 ± 0.03
Semi-quantitative			
AUC60 (norm. unit)	0.31 ± 0.11	0.23 ± 0.10	0.21 ± 0.05
AUC90 (norm. unit)	0.74 ± 0.28	0.54 ± 0.21	0.50 ± 0.09

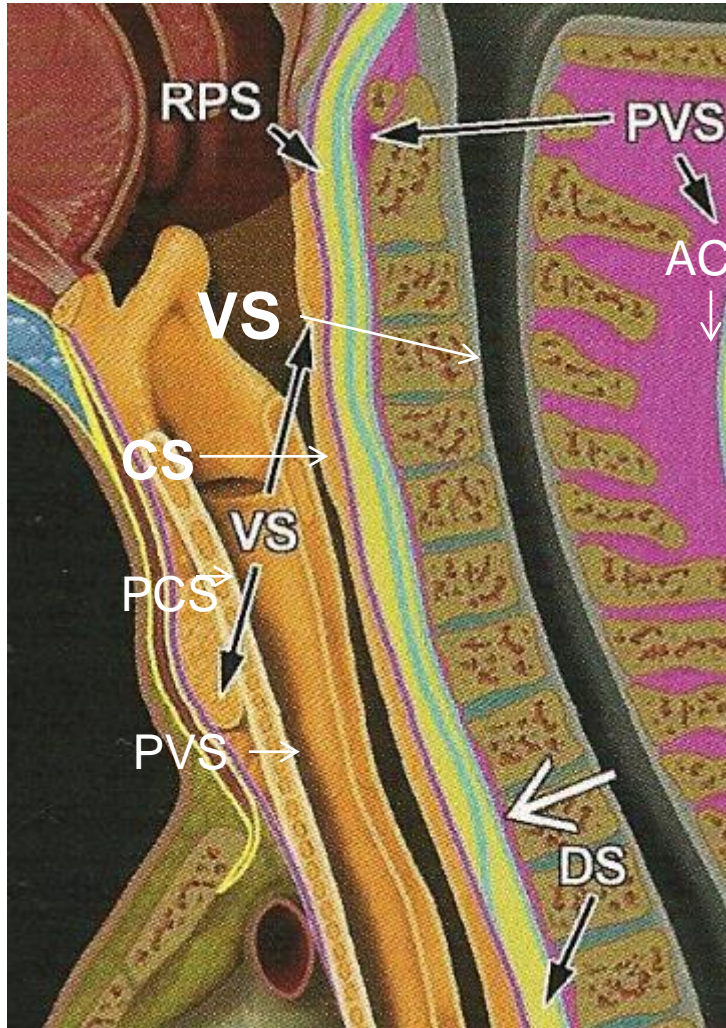
Lee FK-H et al. Dynamic contrast enhancement magnetic resonance imaging (DCE-MRI) for differential diagnosis in head and neck cancers. Eur J radiology 2012; 81:784–788

visceral space

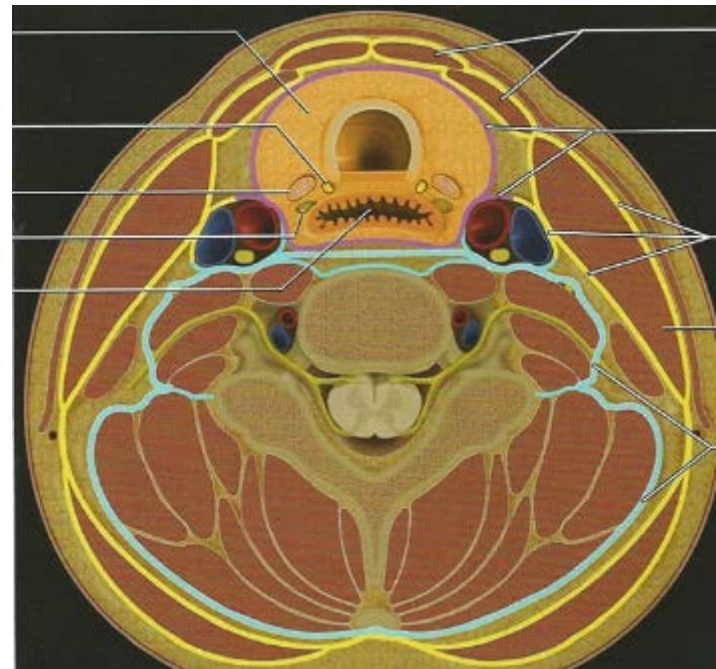
hyoid → mediastinum

content:

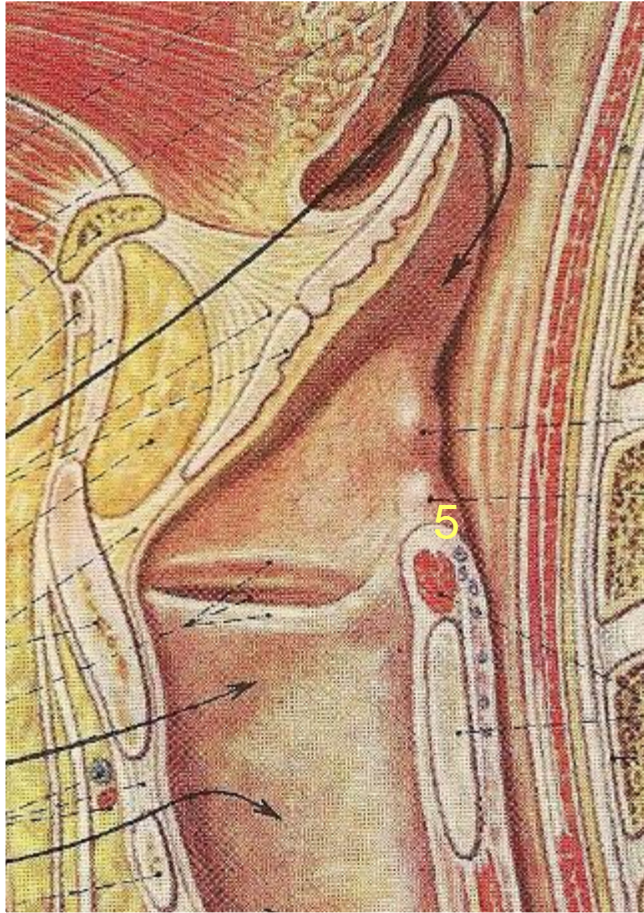
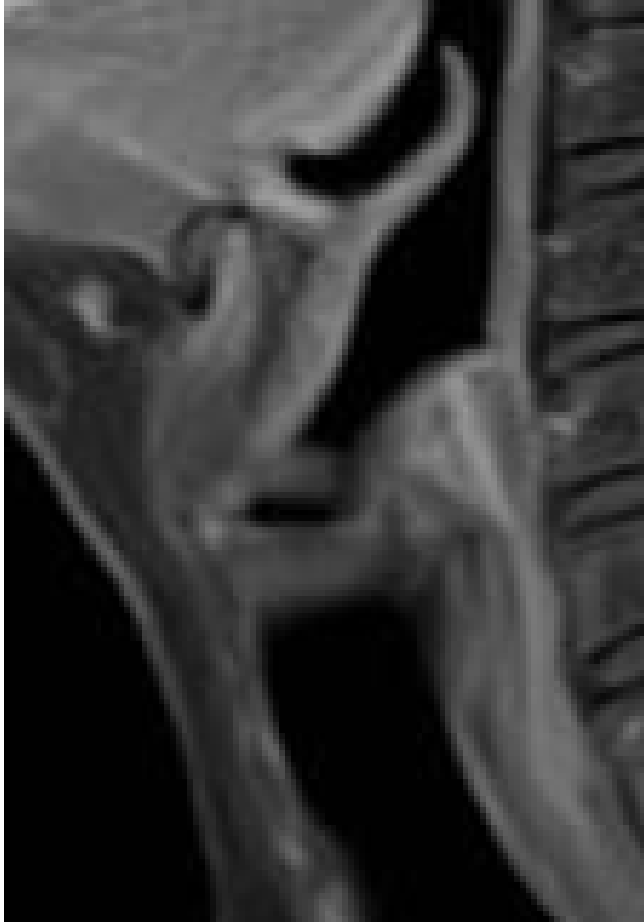larynx
trachea
hypopharynx
cervical esophagus
(para-)thyroid(s)
recurrent laryngeal n.
Ln (pre- & paratracheal)



visceral space – middle sheet
anterior cervical space
carotid space
retropharyngeal space
«danger space»



subdivision of the larynx

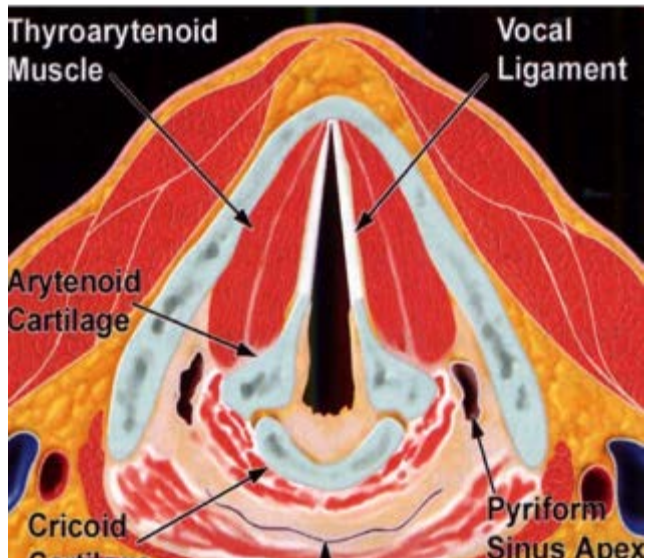
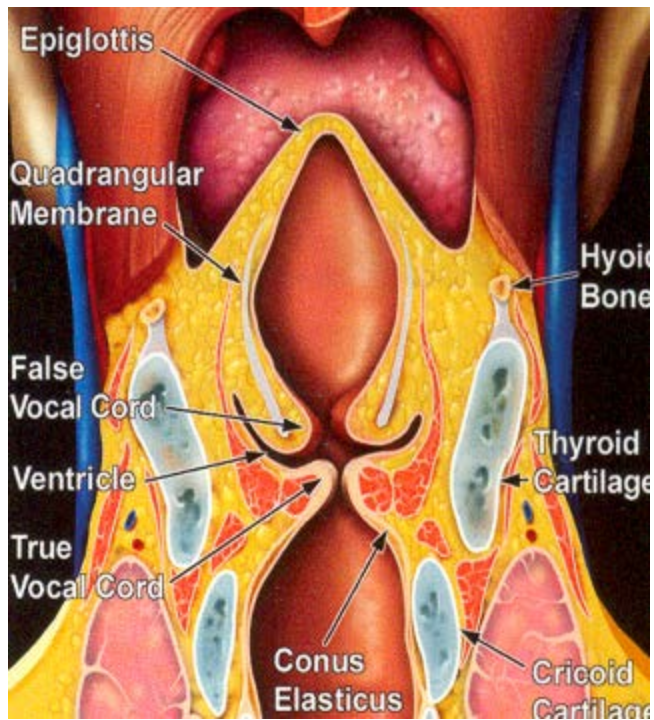


supraglottic

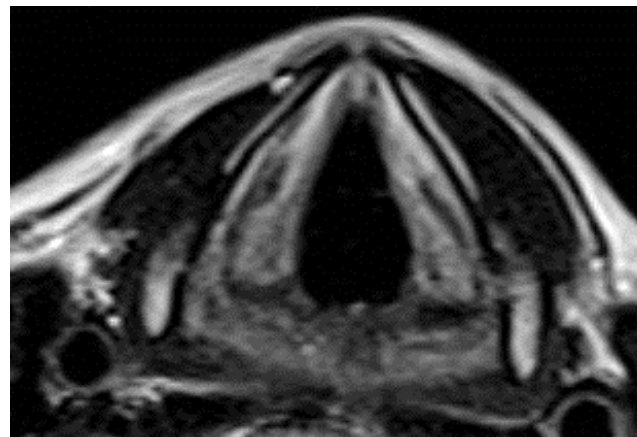
glottic

subglottic

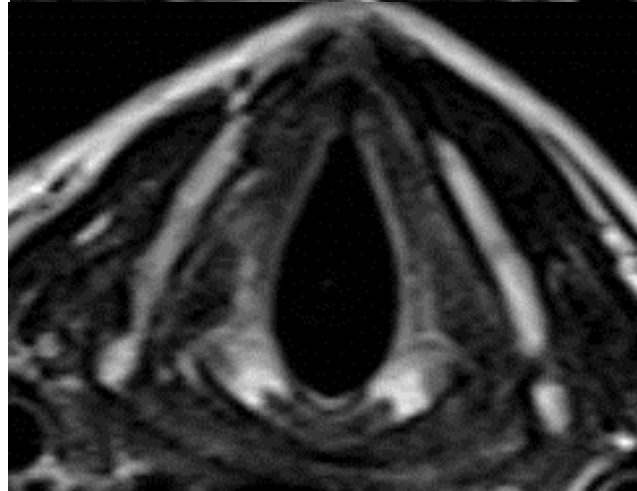
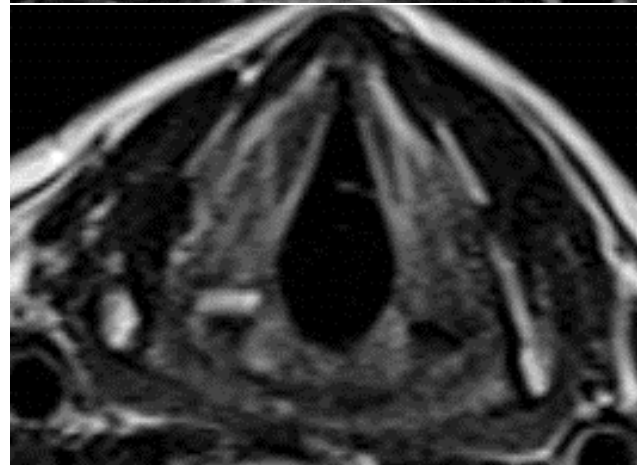
transverse + oblique arytenoid mm.



m. vocalis = medial fibers of thyroarytenoid m.



T2 space
1.2mm



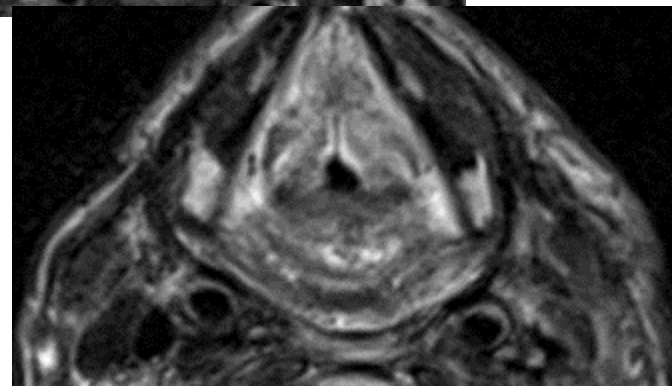
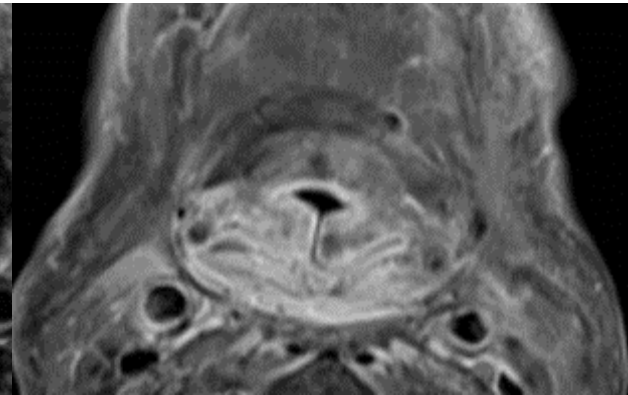
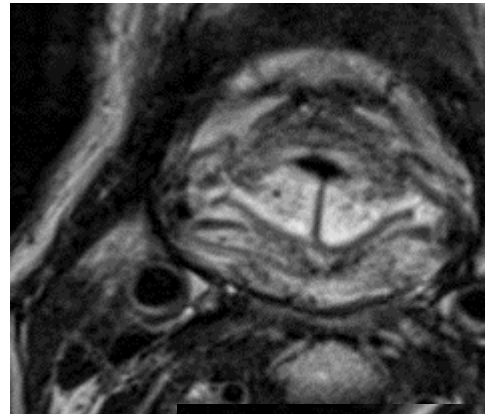
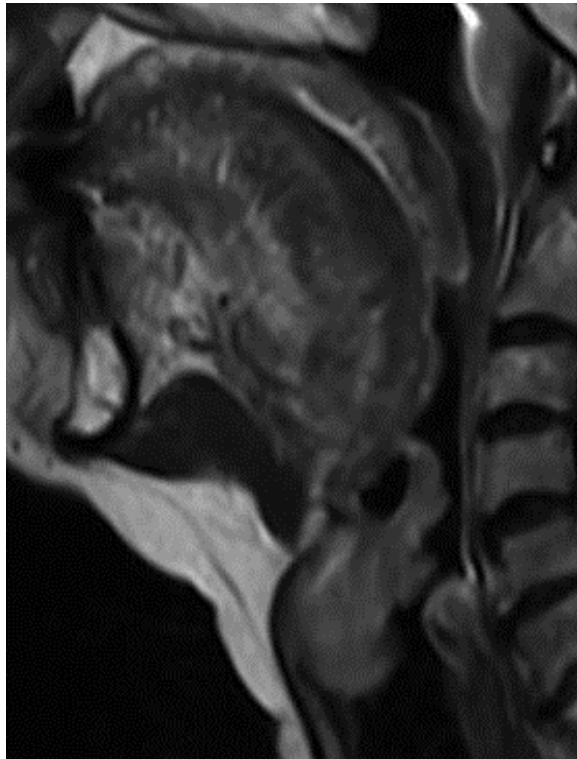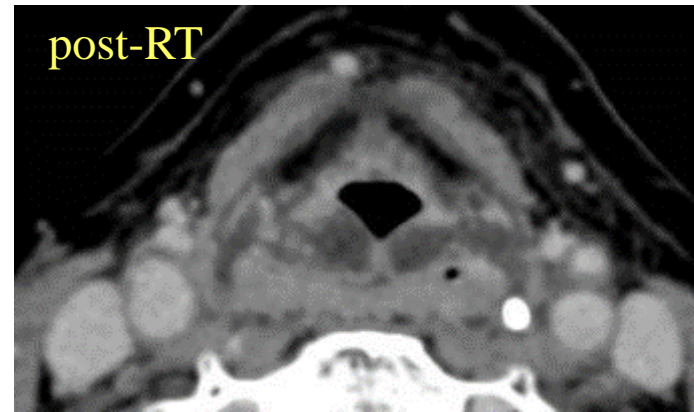
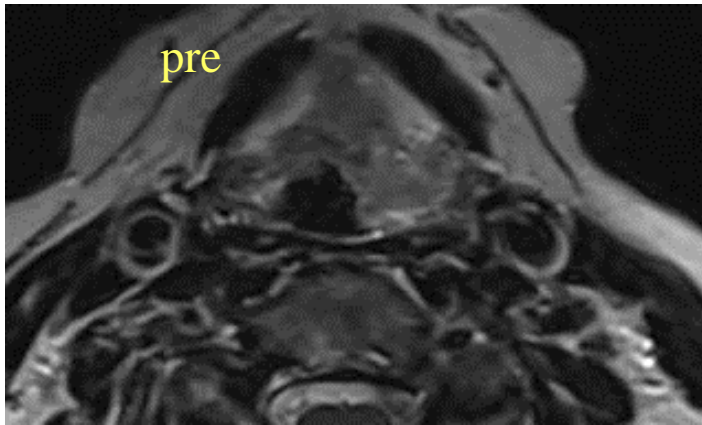
laryngeal cancer

90% SCC

- supraglottic 30% → pre-, paraglottic ?
In 38-50% (20-25% bilat)
- glottic 65% → ant. commissure, contralateral vocal cord
para-/subglottic extension, laryngeal skeleton & involvement of extralaryngeal space ?
In 10-25% over all / T2 5%, T3 18%, T4 32%
- subglottic 2- 5%
→ trachea (thyroid, esophagus) ?

supraglottic laryngeal-cancer

post-RT edema



T classification glottic cancer

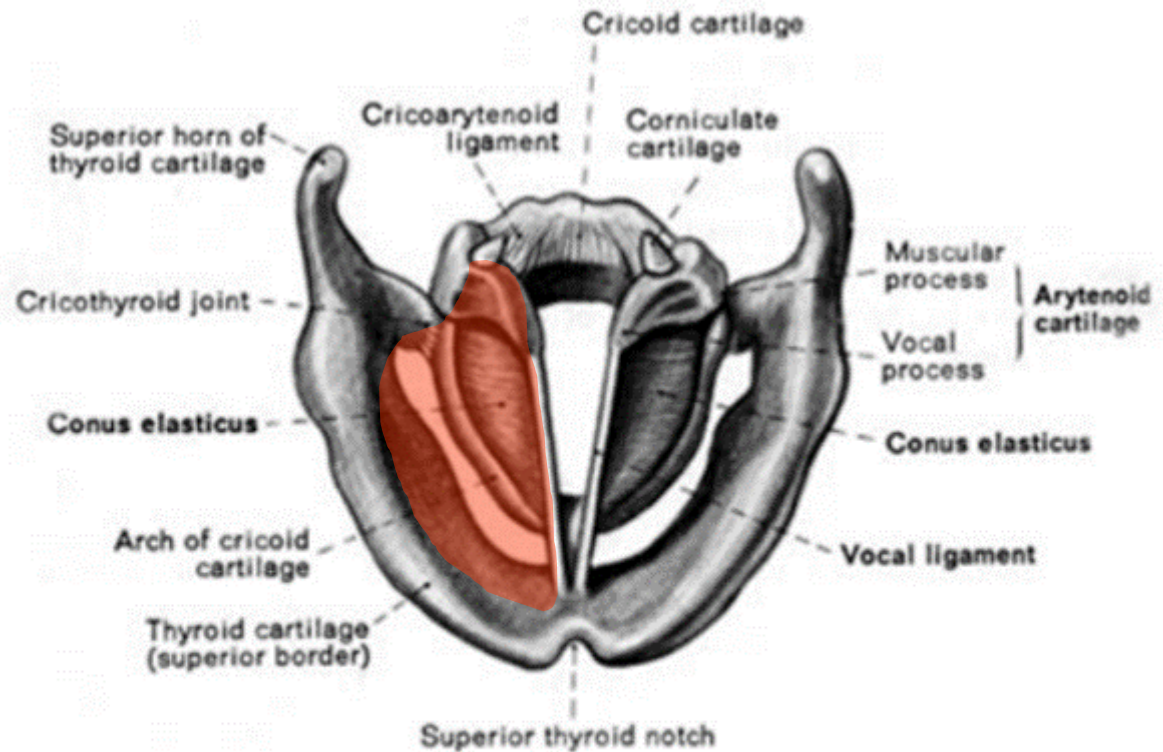
- T1: tumour confined to vocal cord(s) (\pm ant. or post. commissure)
mobility not impaired
 - T1a: tumour confined to one vocal cord
 - T1b: tumor affects both vocal cords
- T2: extension to supraglottic &/or subglottic space, &/or impaired vocal cord mobility
- T3: tumour confined to the larynx, paraglottic &/or infiltration of the inner layer of thyroid cartilage, fixed vocal cord
- T4: tumour breaches thyroid cartilage, &/or extralaryngeal extension (e.g. trachea, thyroid, pharynx)

quadrangular membrane
«towel of connective tissue»
epiglottis to arytaenoid
cartilages

Conus elasticus

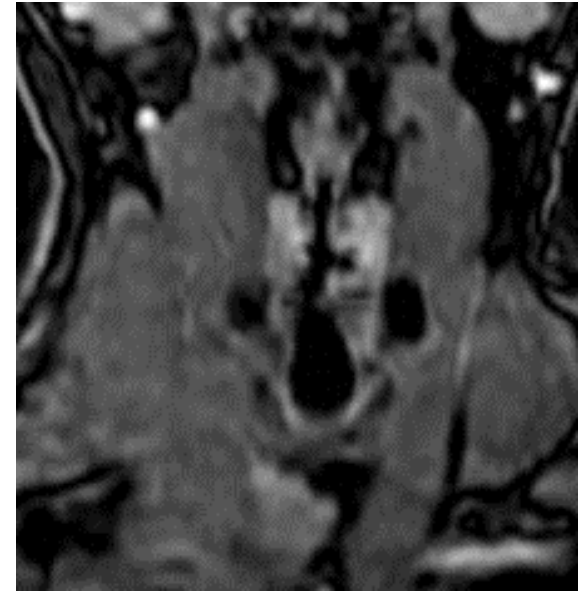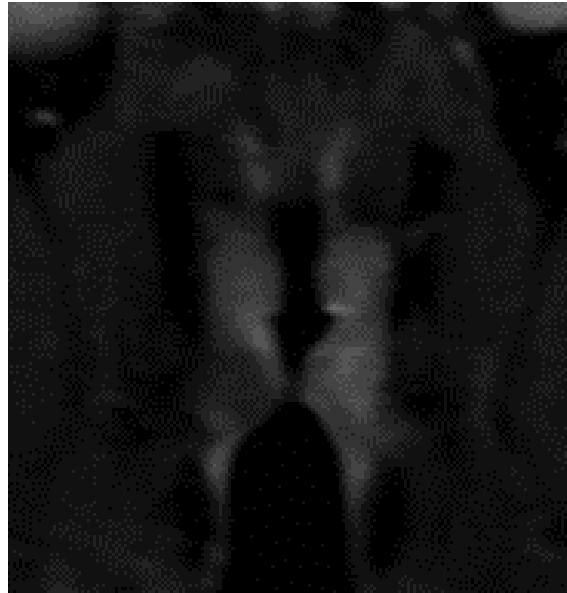
Broyle's Ligament: no peri-
chondrium

Hyoepiglottic ligament: «roof»
Of the para- & preepiglottic
space



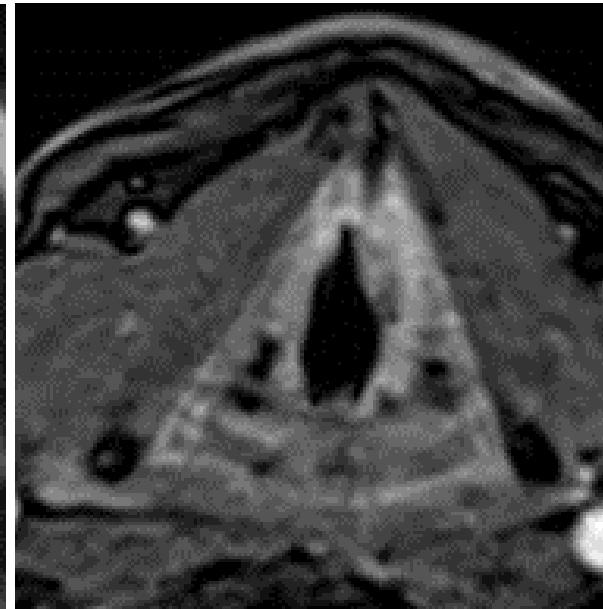
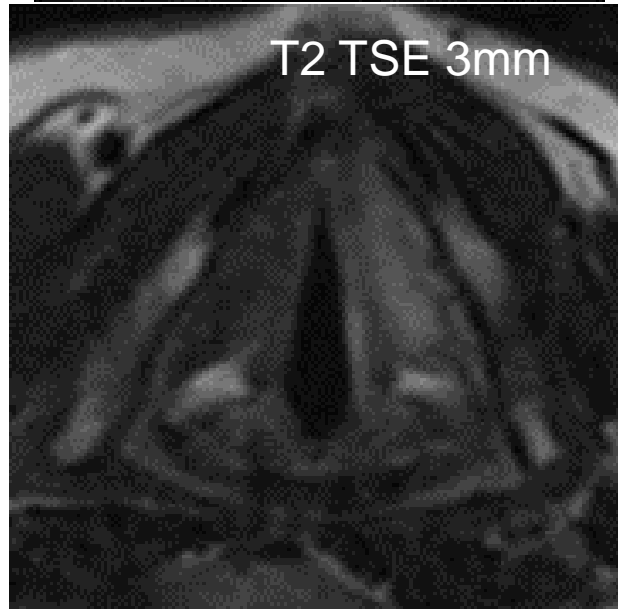
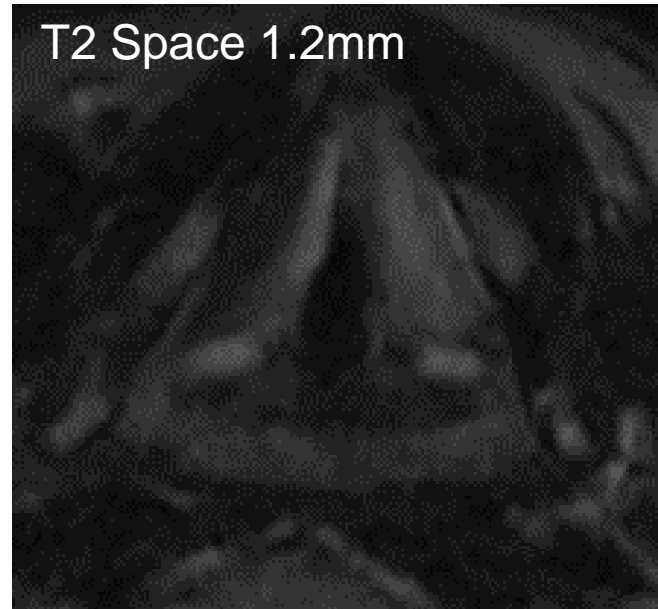
glottic Ca with paraglottic extension (T3)

supra-subglottic ?
paraglottic \pm cartilage ?



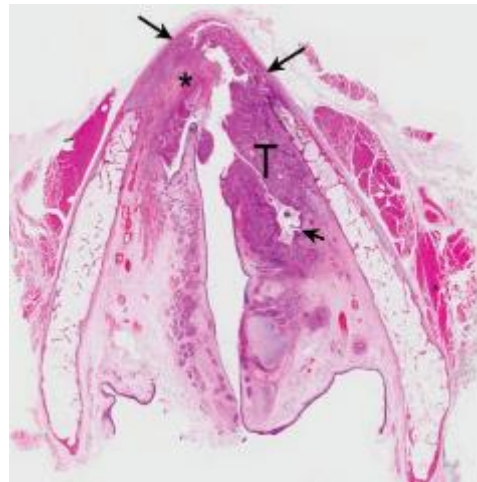
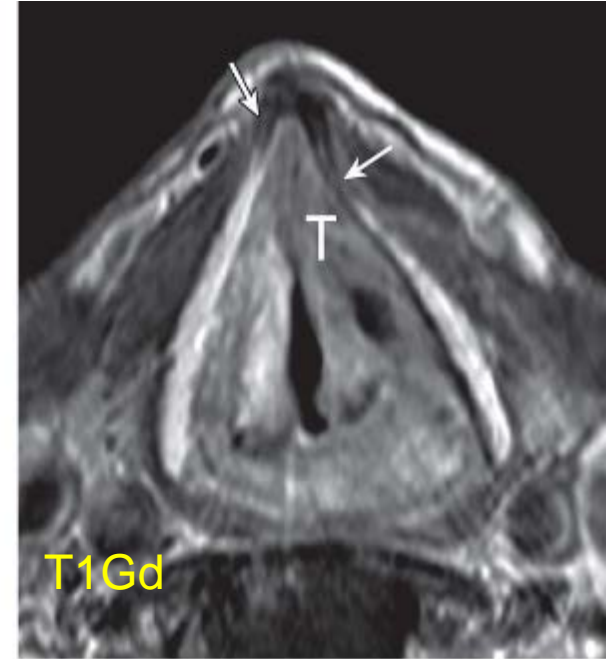
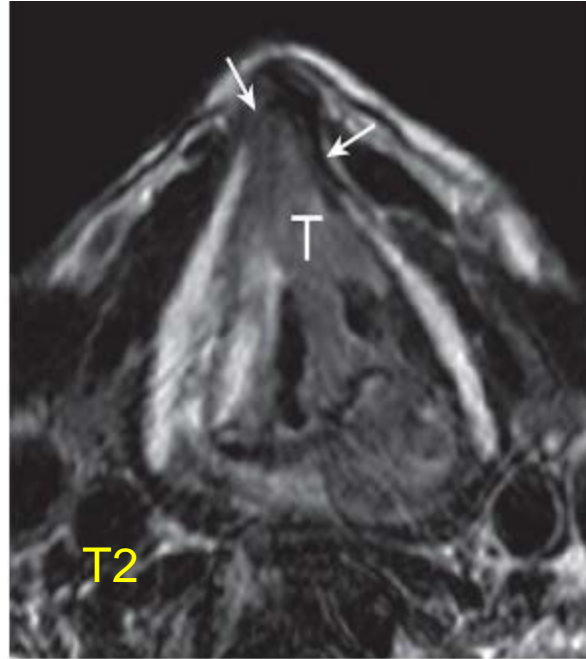
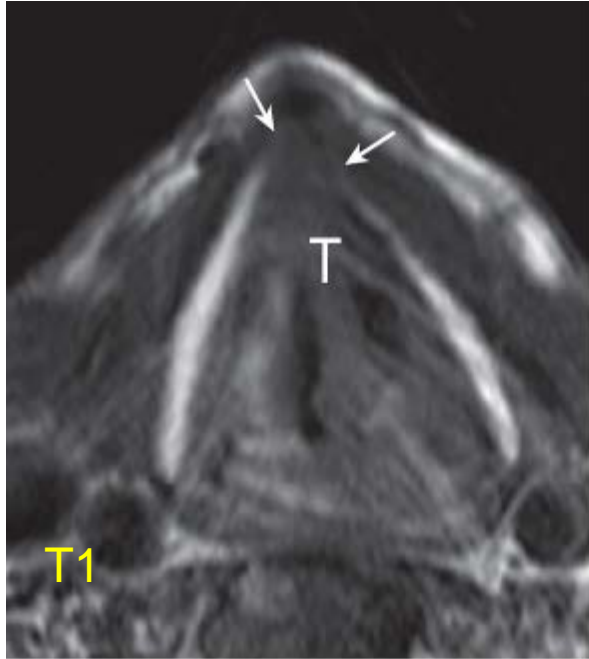
T2 Space 1.2mm

T2 TSE 3mm



MP 1946 increasing hoarseness, fixed vocal cord

infiltration of thyroid cartilage



Resonance thyroid cart. when involved with tu

T 1	low
T2	~ tumour
T1 + Gd	~ tumour

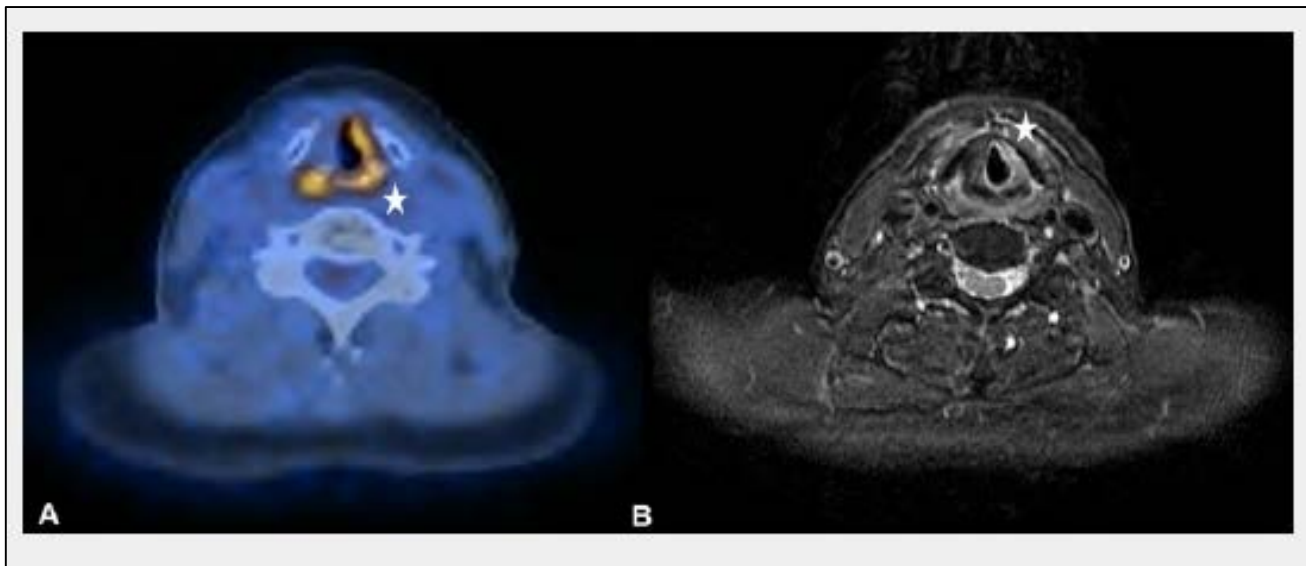
Resonance thyroid cart. + inflammation

T 1	low
T2	> tumour
T1 + Gd	> tumour

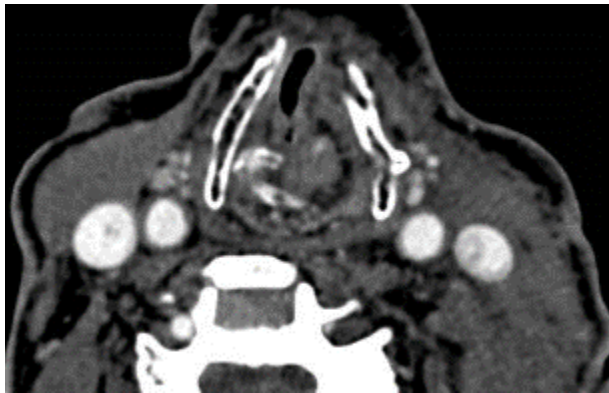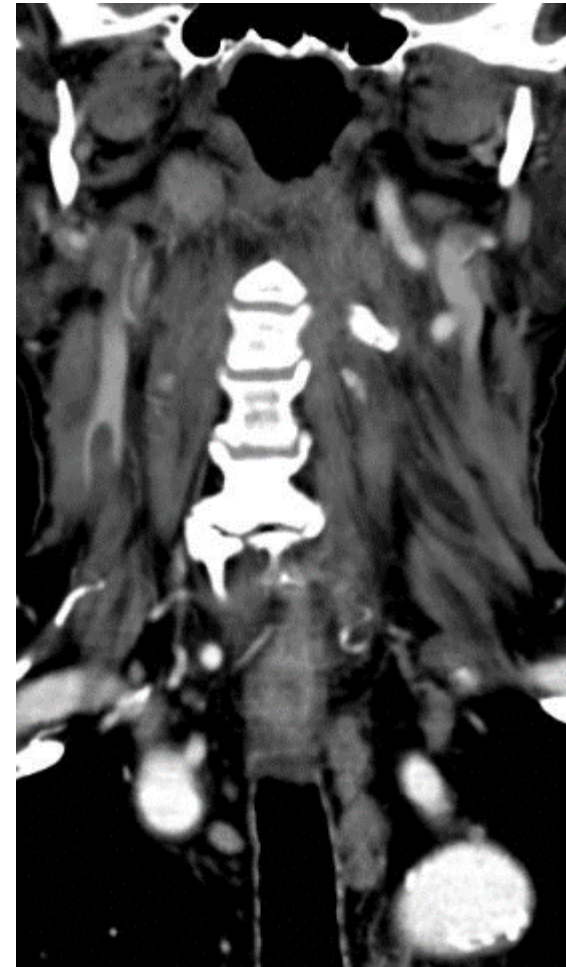
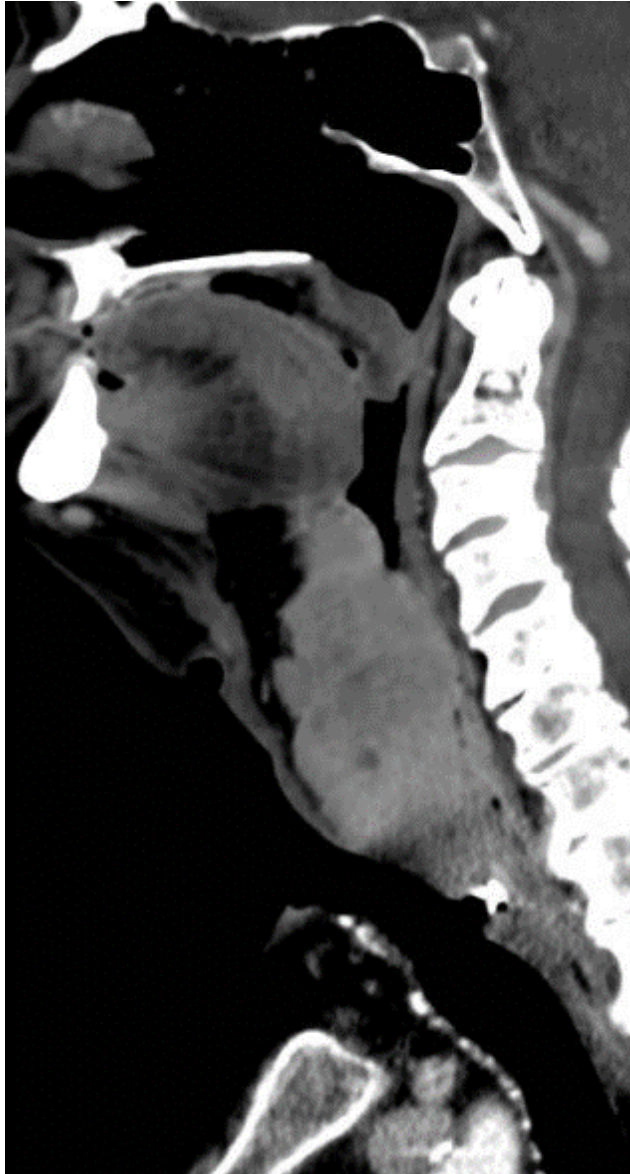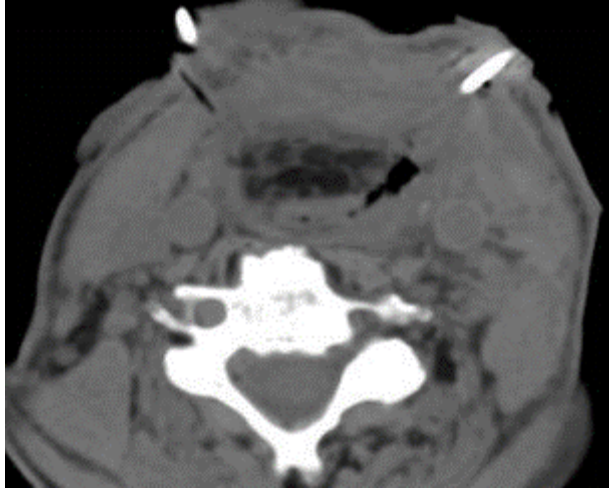Identification of a morphologic correlate in PET-positive findings

How aggressively shall we take biopsies?

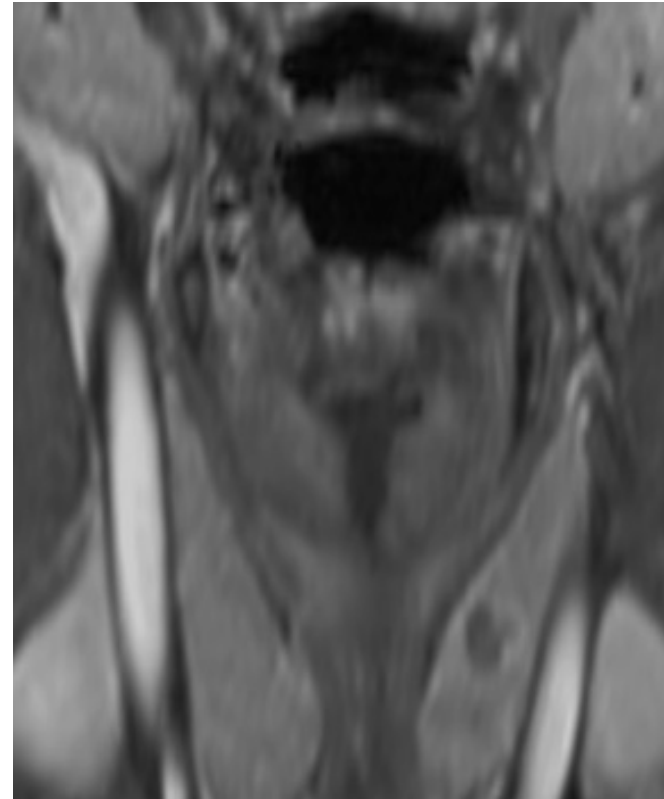
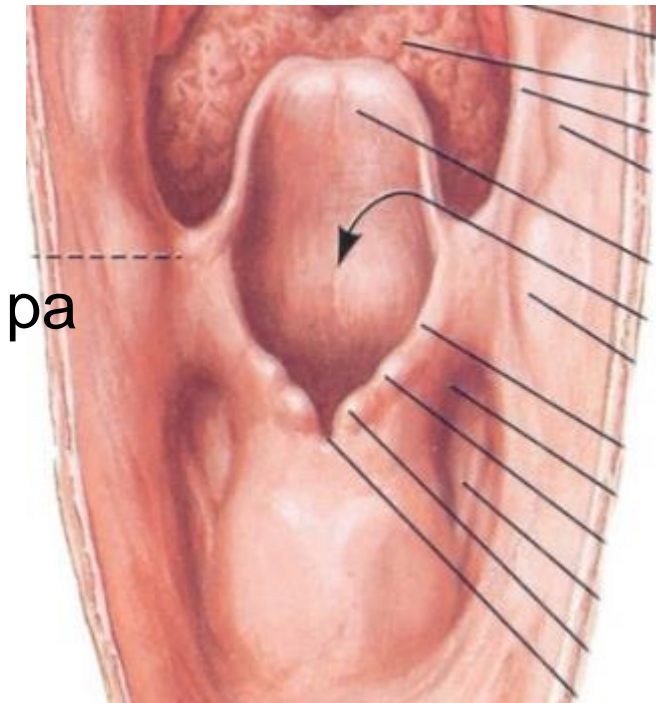
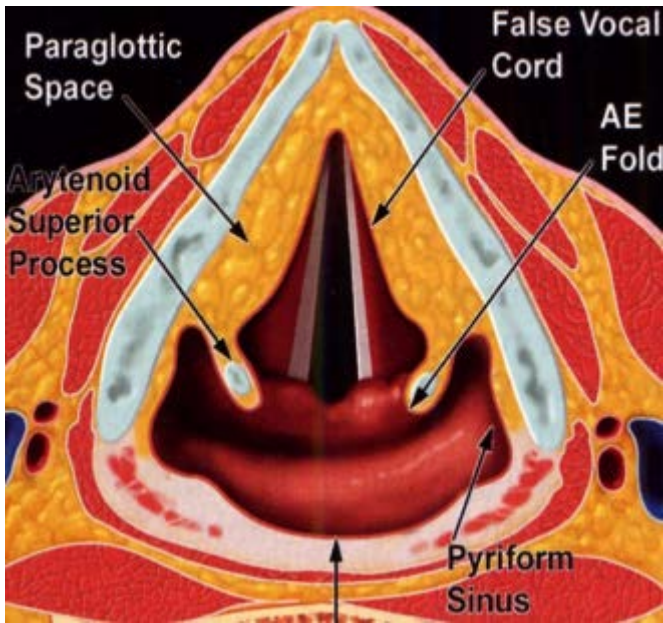
- Meerwein C et al. Post-treatment surveillance of head and neck cancer: pitfalls in the interpretation of FDG PET-CT/MRI. Swiss Med Wkly. 2015 Feb 21



post laryngeal cancer



hypopharynx:



piriform sinus; postcricoid region, posterior wall of pharyngeal wall

hypopharyngeal cancer

- piriform sinus 60%
- postcricoid region 25%
- posterior wall 15%

- 10% synchronous/ 25% metachronous primaries
- 50-75% metastatic lymph nodes
- prognosis: piriform sinus > posterior wall > postcricoid

staging

hypopharyngeal- cancer:

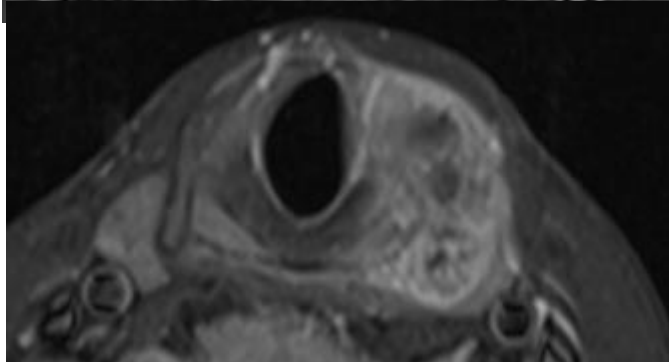
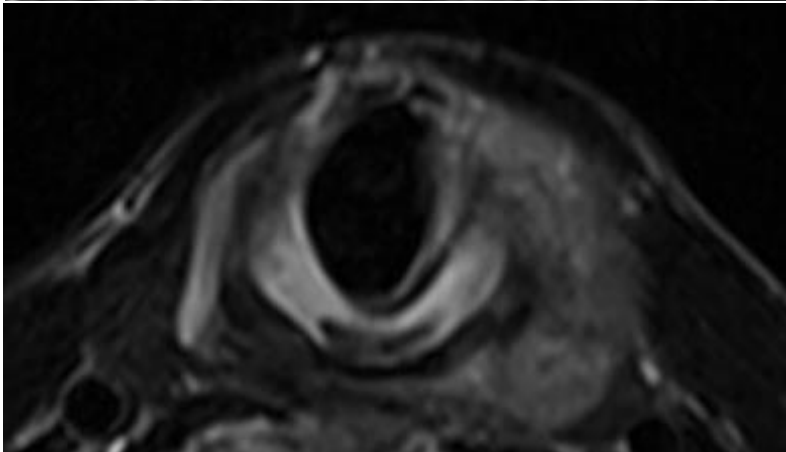
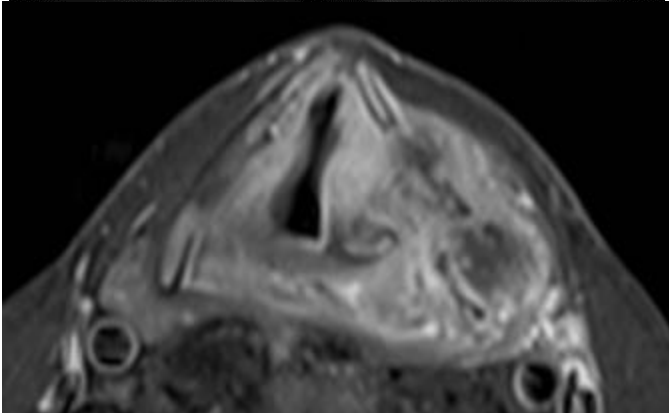
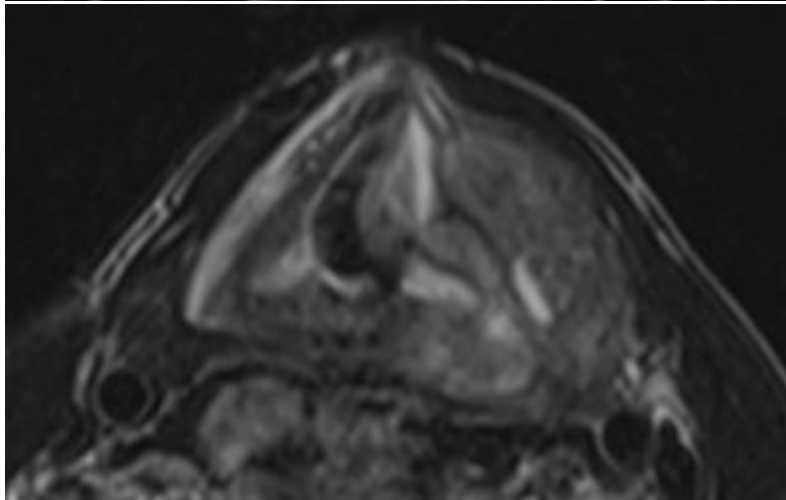
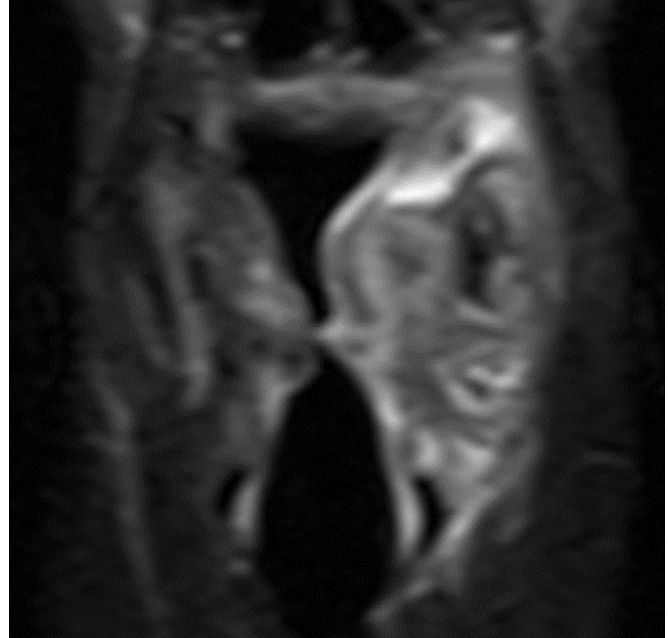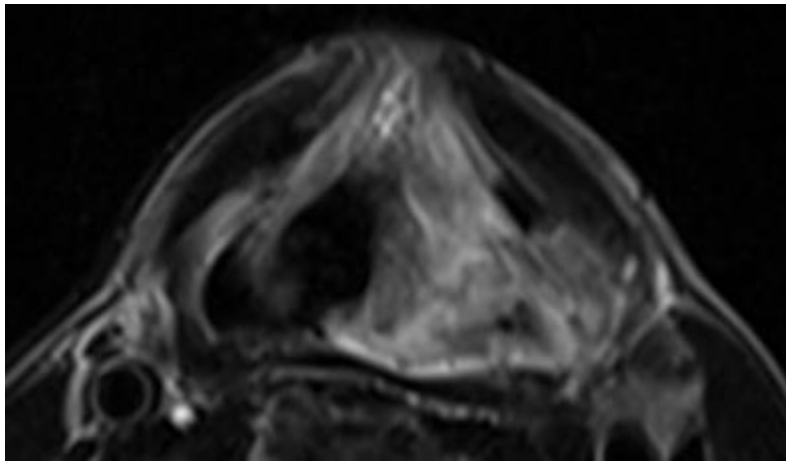
T1: Tu infiltrates 1 „region“ of hypopharynx is $\leq 2\text{cm}$ in maximal extension

T2 : Tu infiltrates > 1 „region“ of hypopharynx &/or adjacent region, 2-4cm Ø, no laryngeal fixation

T3: Tu $> 4\text{cm}$ maximal extension or laryngeal fixation

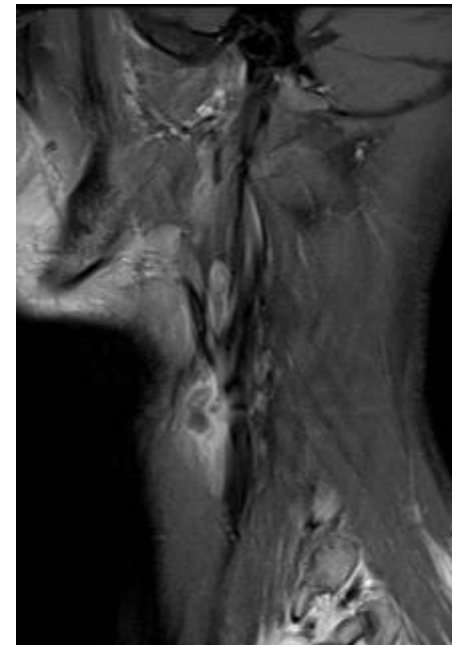
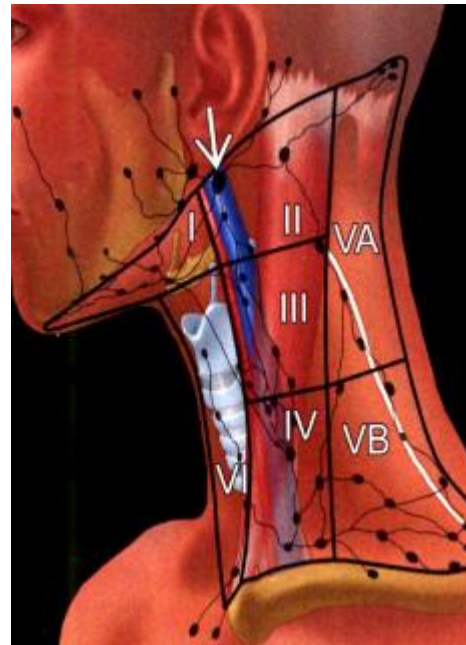
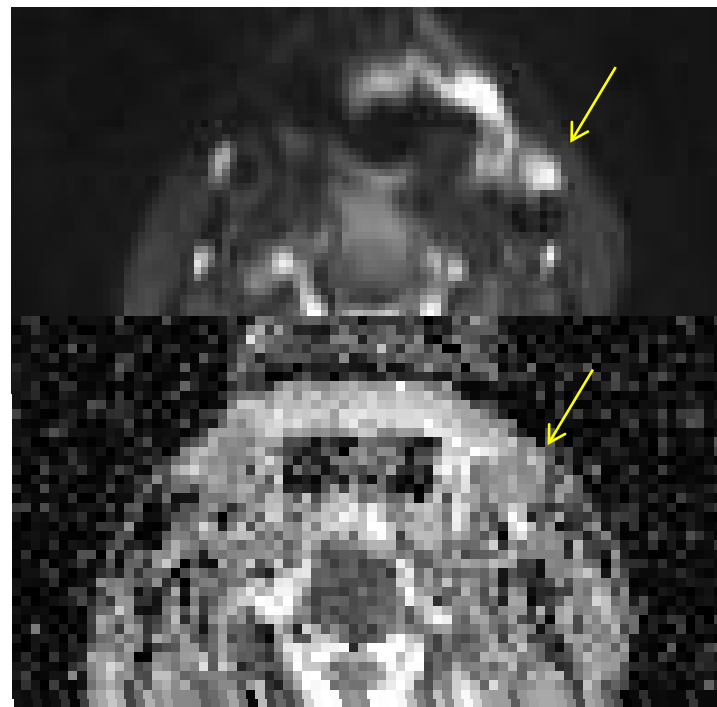
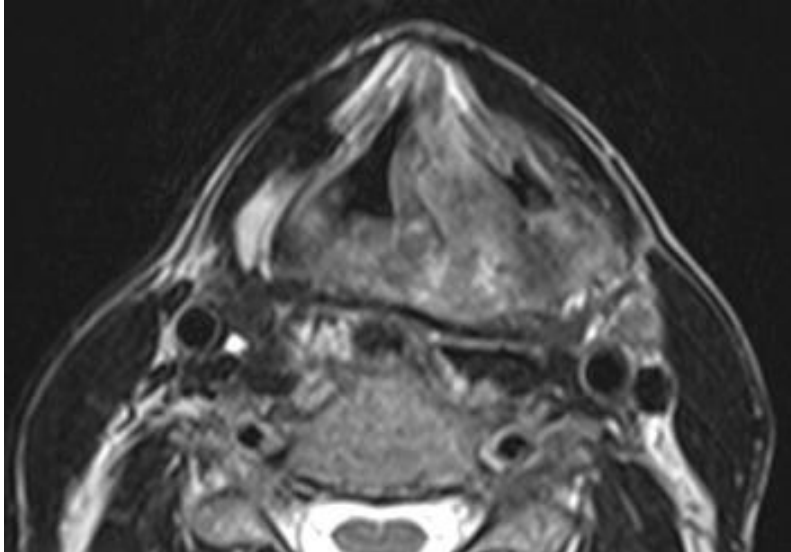
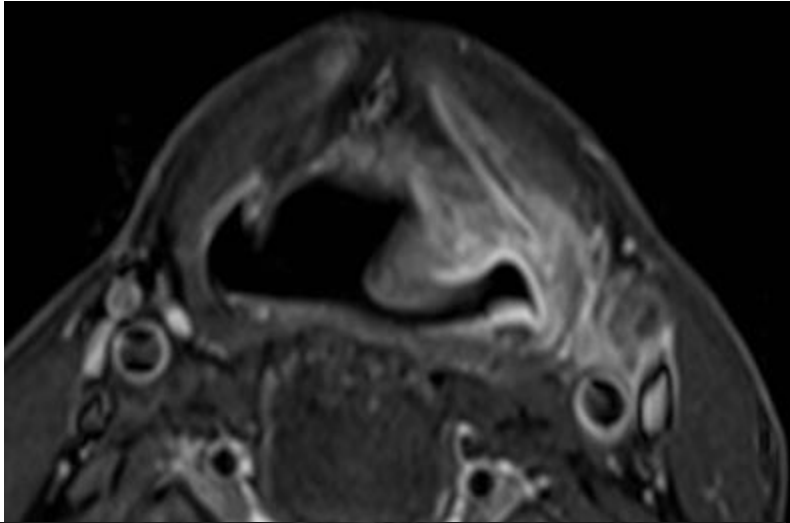
T4a: Tu infiltrates thyroid-, cricoid cartilage, hyoid, thyroid, esophagus, or soft tissues

T4b: Tu infiltrates prevertebral fascia, encases ICA, infiltrates mediastinum



In mets

Level III



parotid-Space

tumours

- benign: pleomorphic adenoma, cystadenolymphoma (Whartin), oncocytoma, schwannoma of the facial nerve, lipoma...
- malignant: ACC, mucoepidermoid-, acinus cell-, salivary duct carcinoma, adenocarcinoma, Ca ex pleomorphic adenoma, MASC, NHL

In mets: SCC , melanoma, NHL

parotid gland

plane of facial nerve

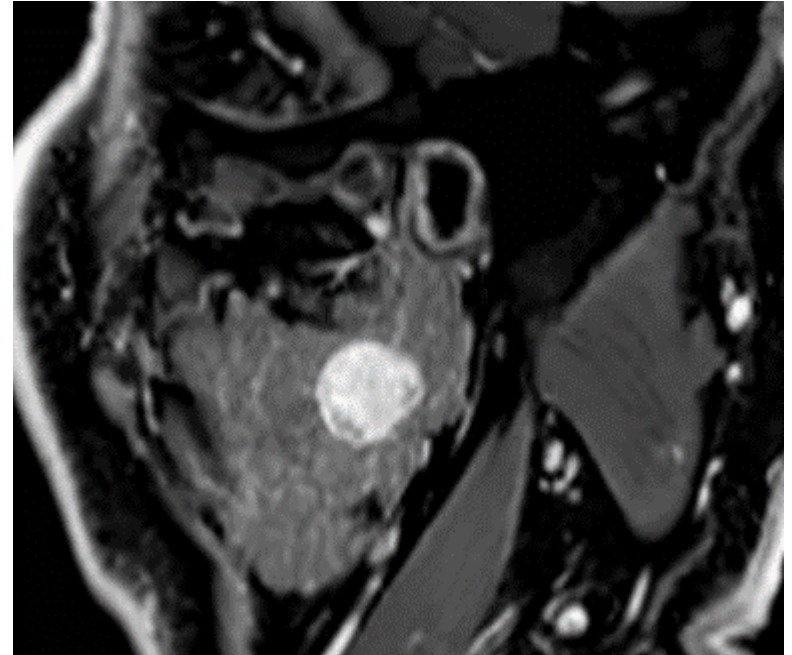
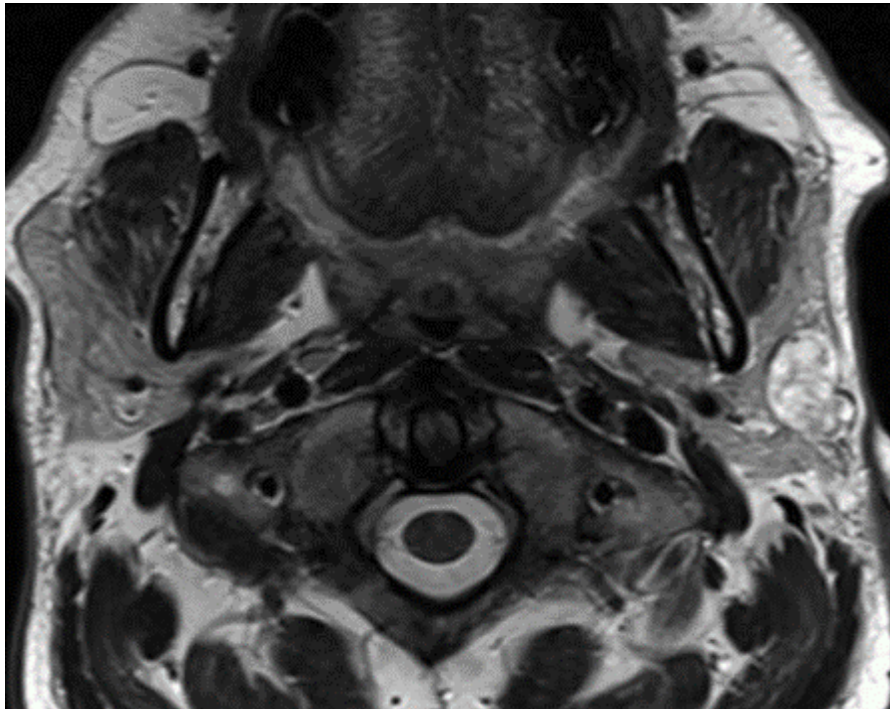
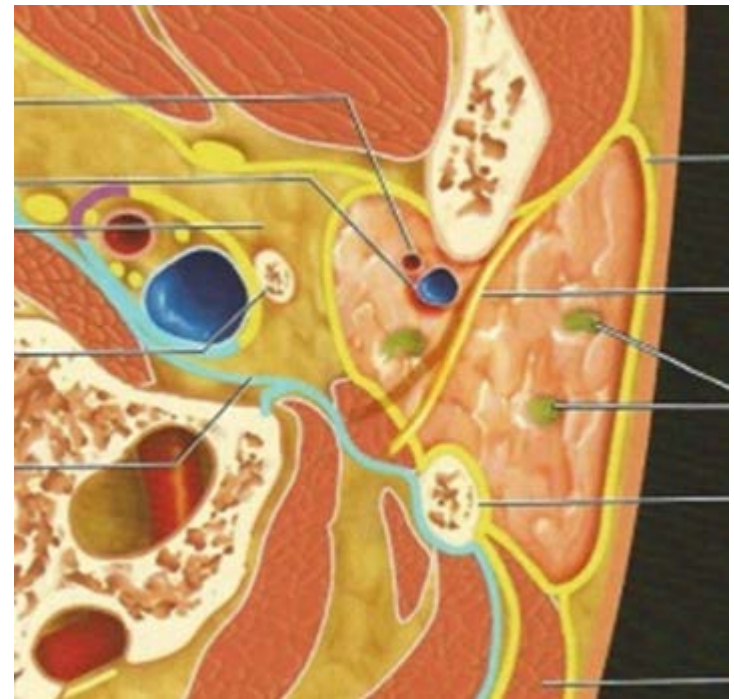
Foramen stylomastoideum – V. retromandibularis)

- superficial lobe
- deep lobe

lymph nodes (~20)

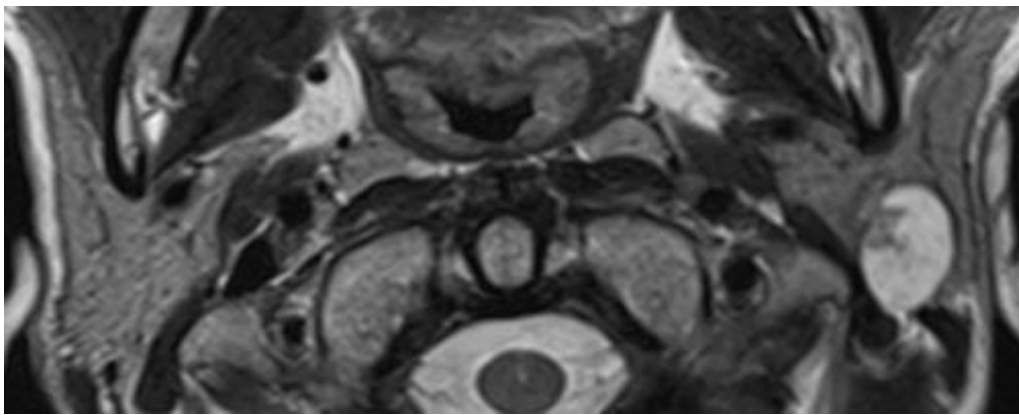
ductus parotideus (Stenson's duct)

accessory lobe(s) (20%)

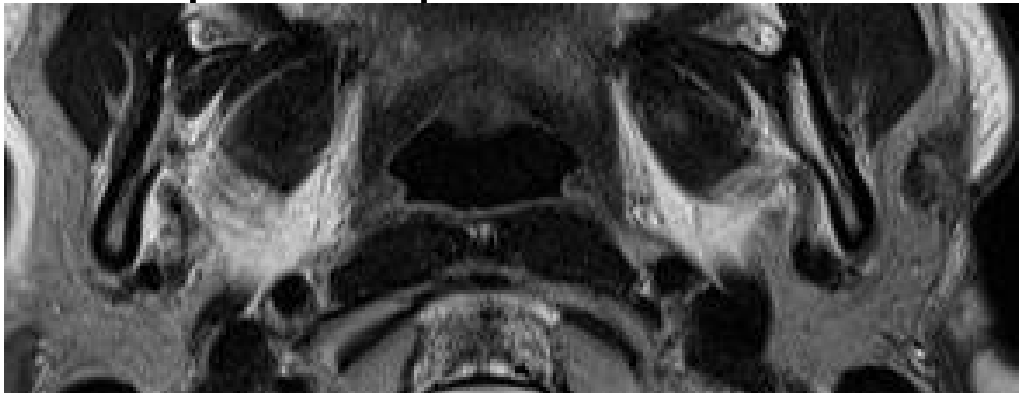

parotid lesions: superficial lobe

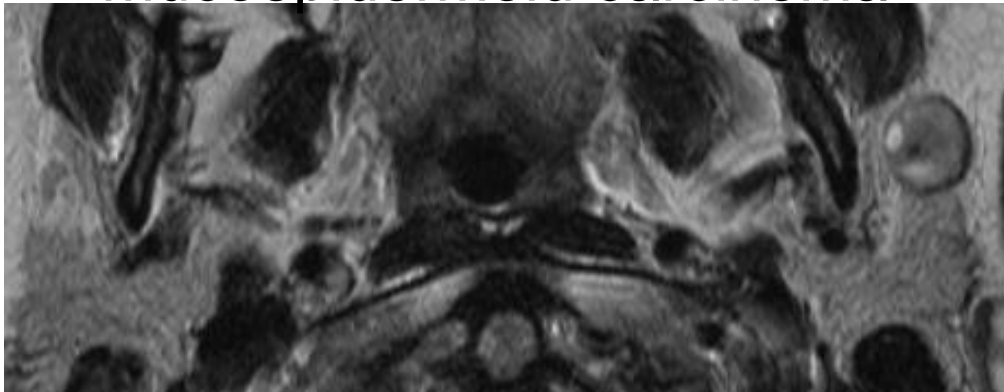
imaging \neq histology



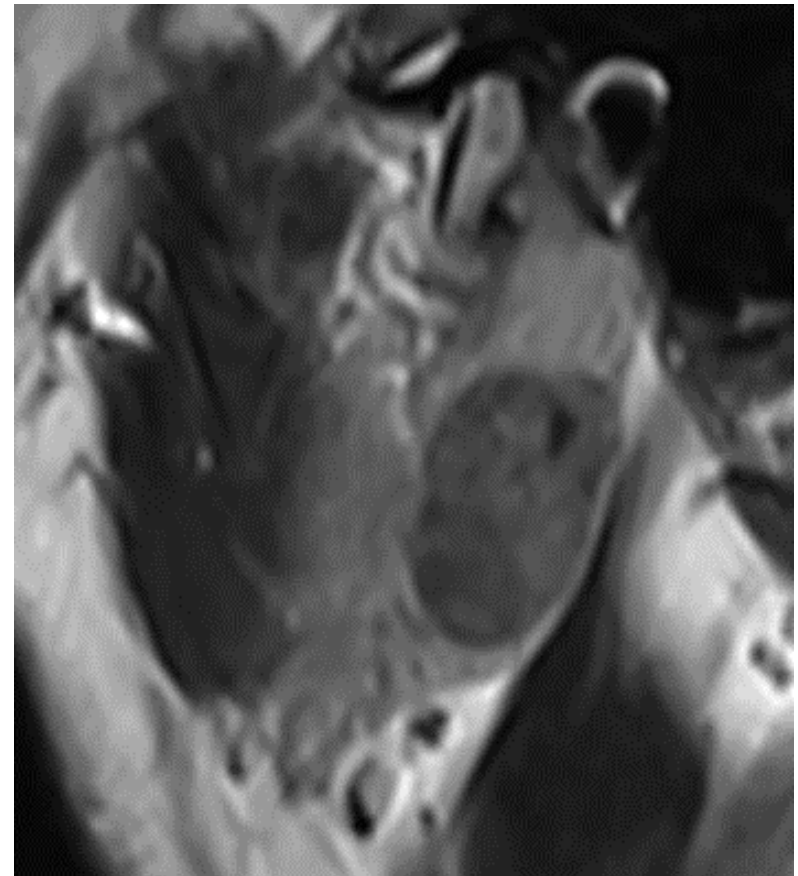
pleomorphic adenoma



mucoepidermoid carcinoma



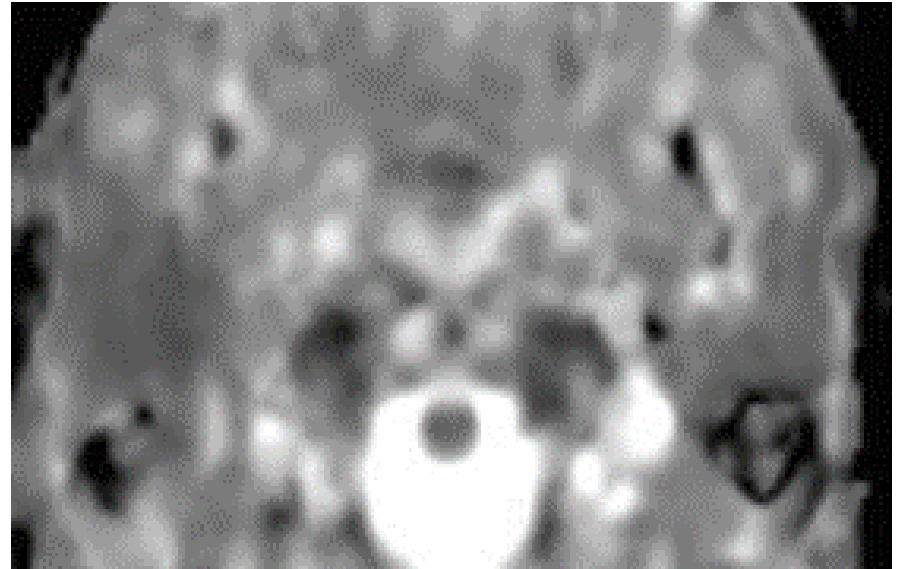
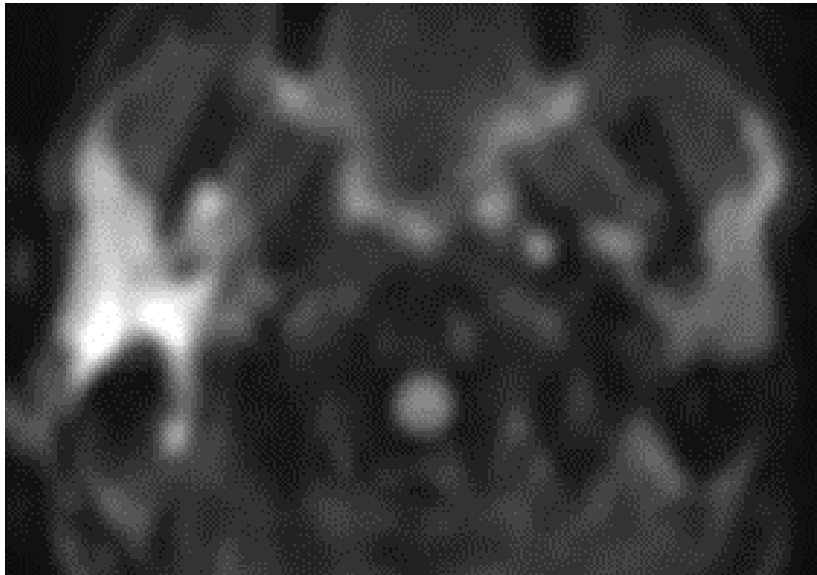
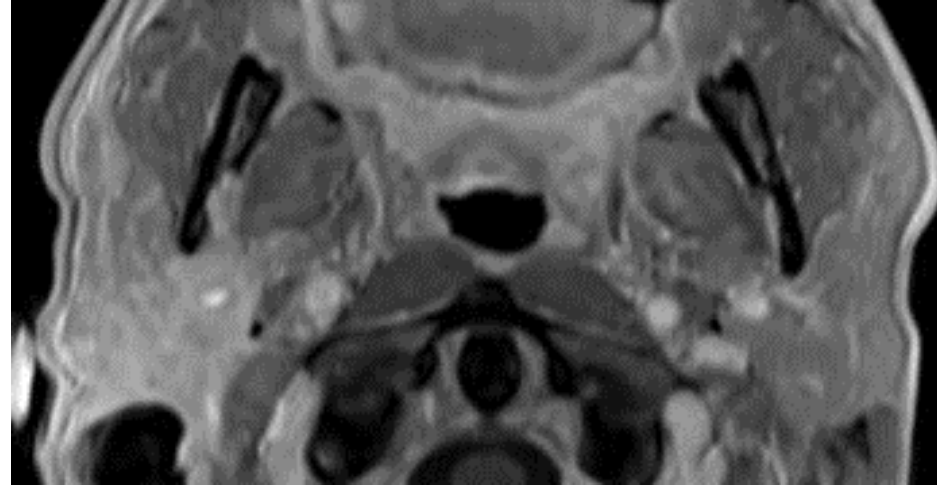
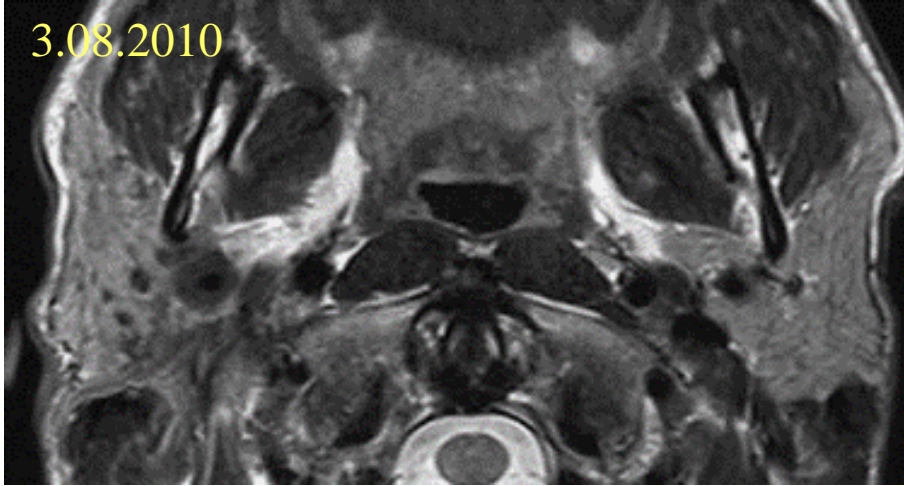
lymph node metastasis



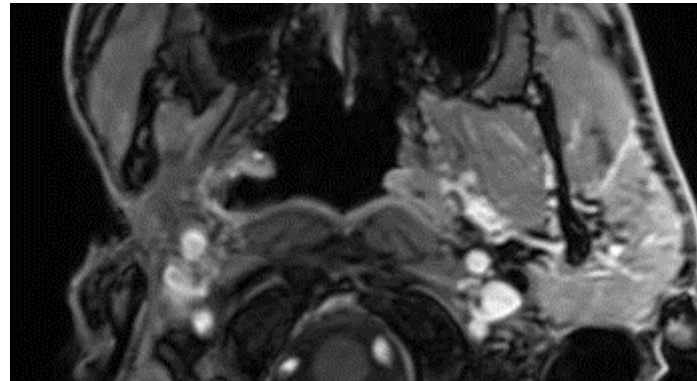
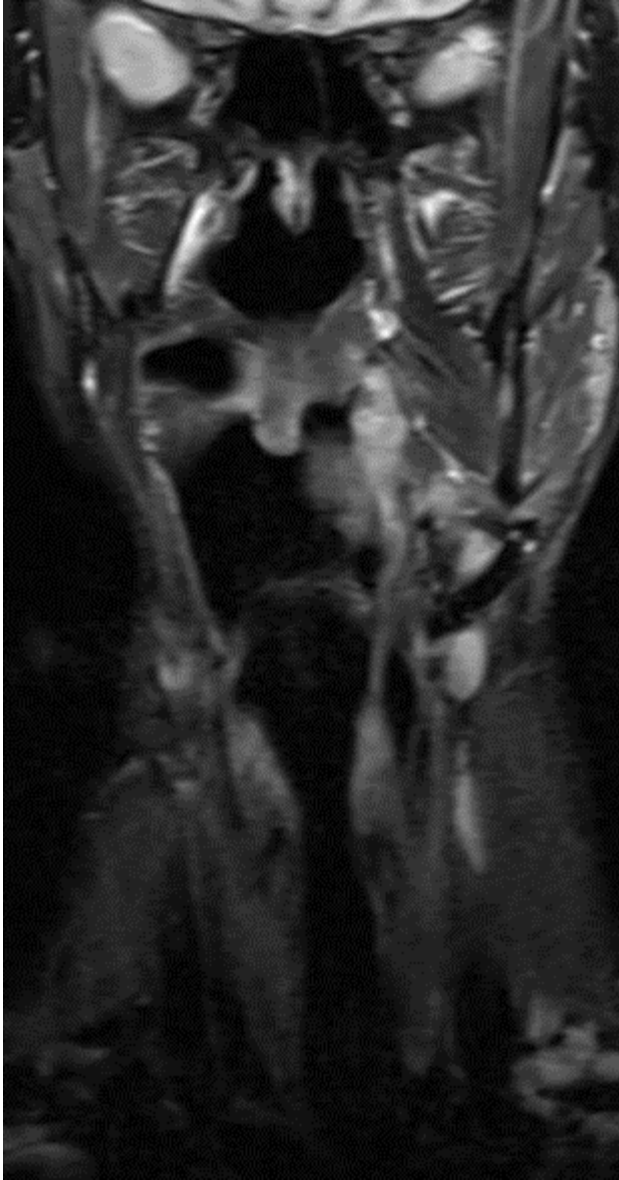cystadenolymphoma

ACC parotid gland

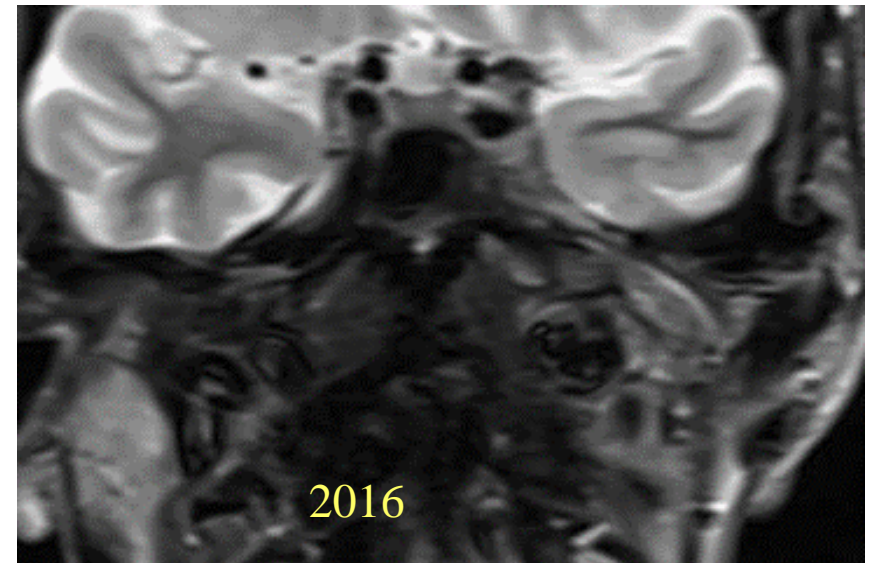
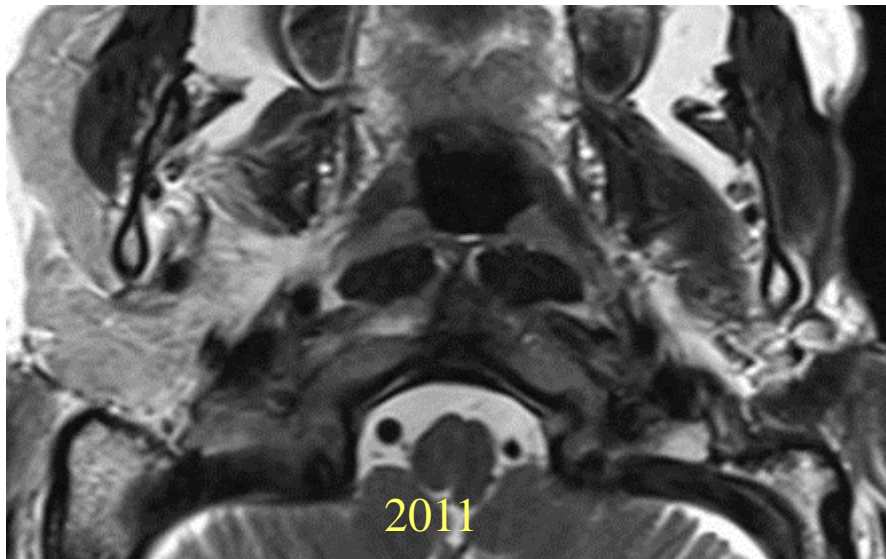
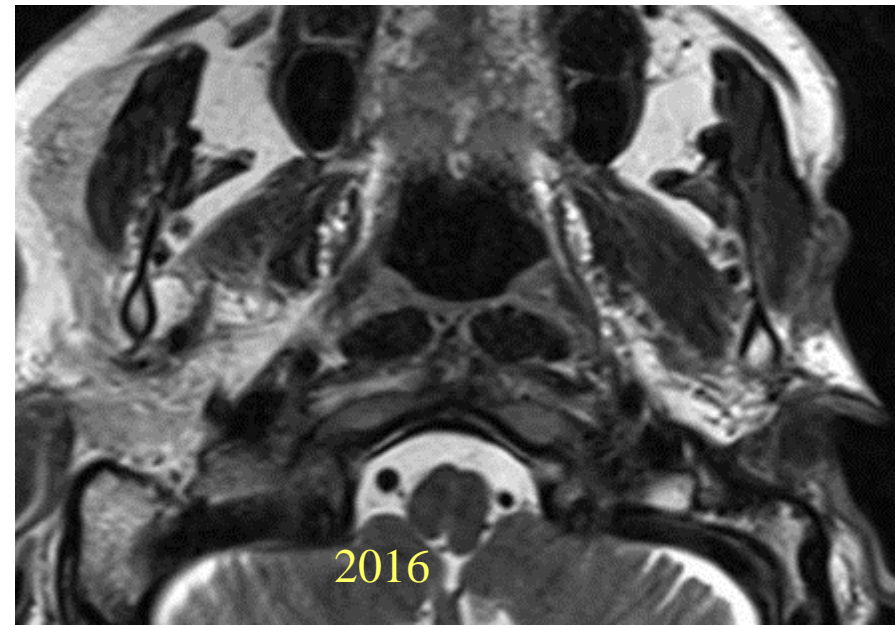
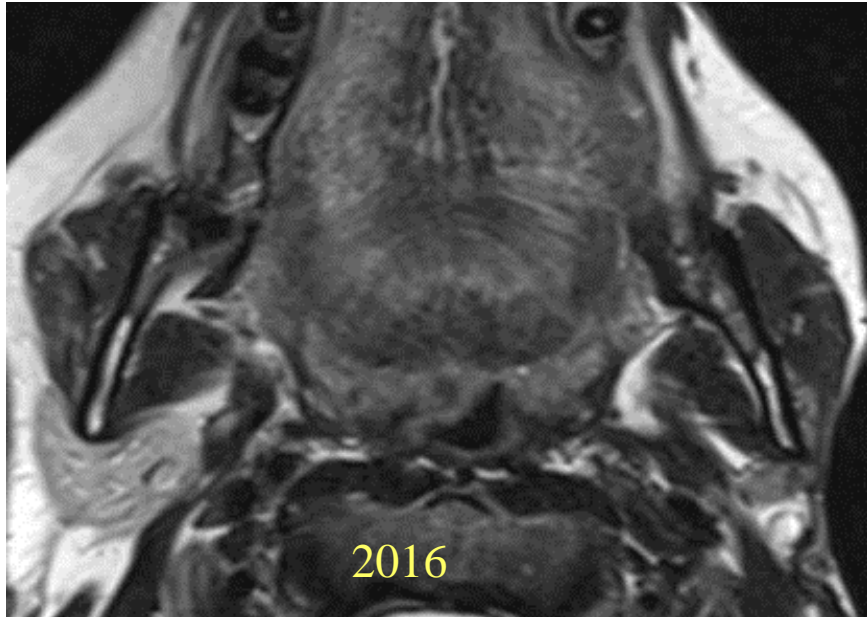
3.08.2010



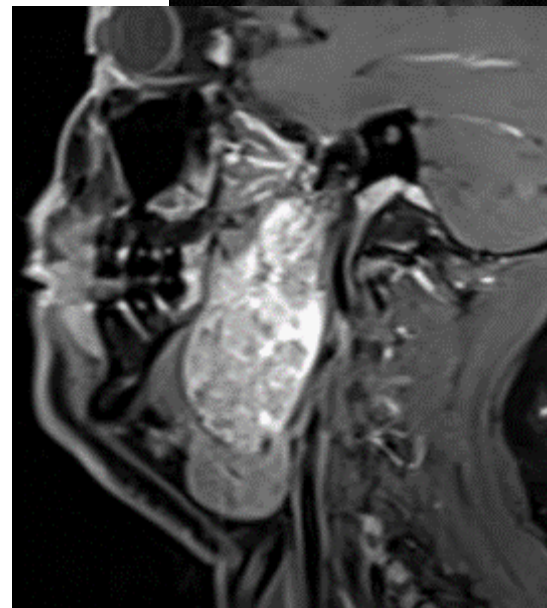
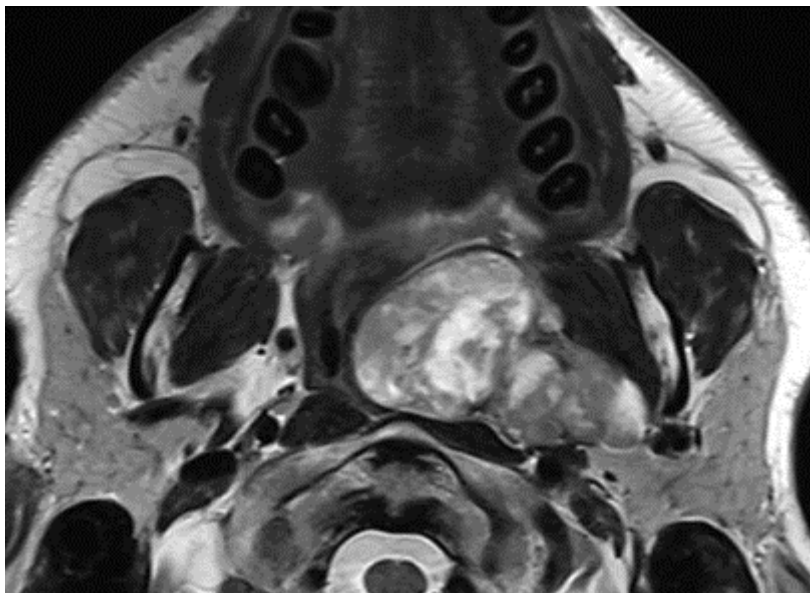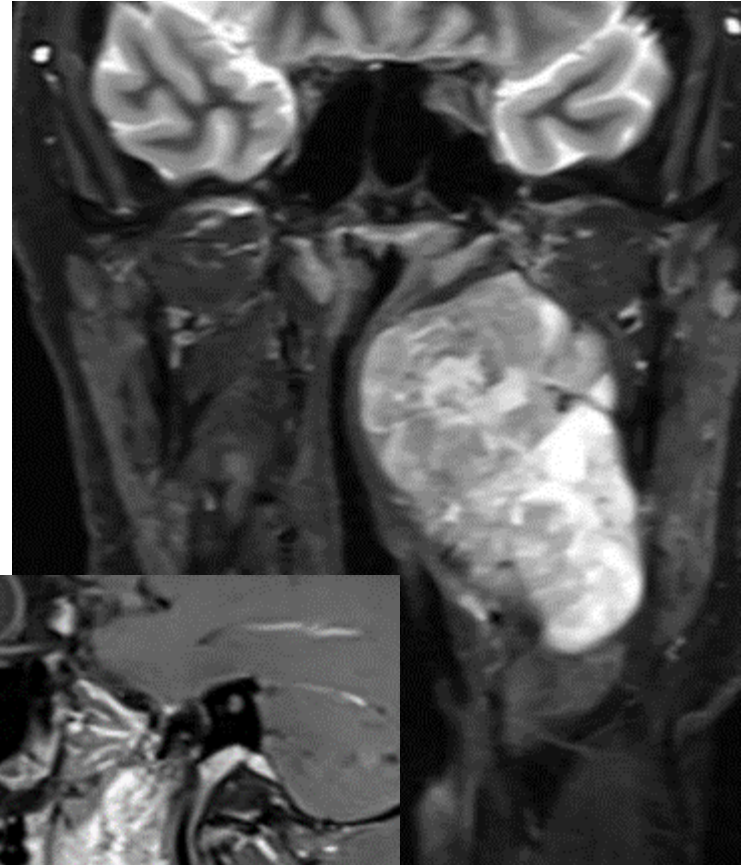
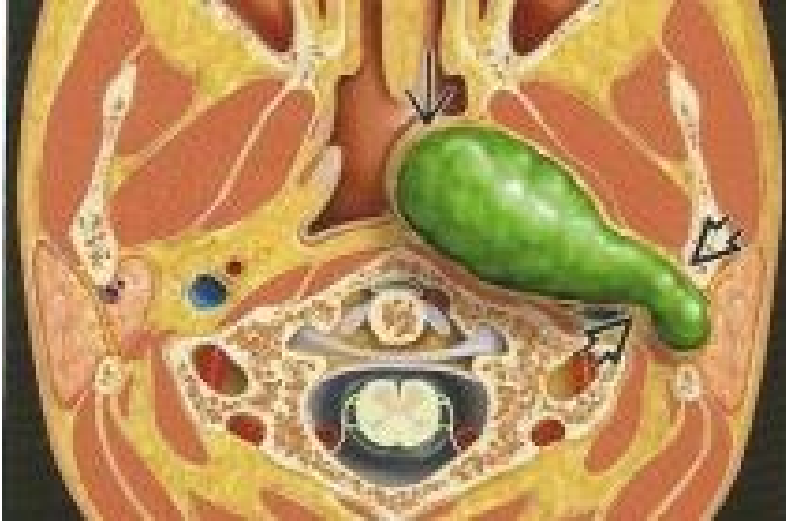postop/RT course



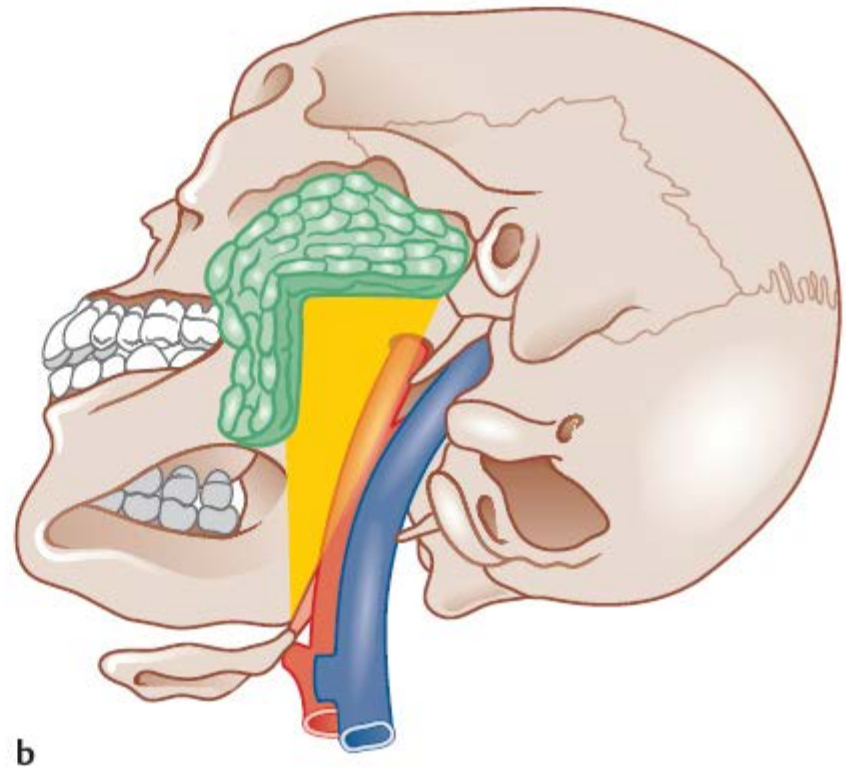
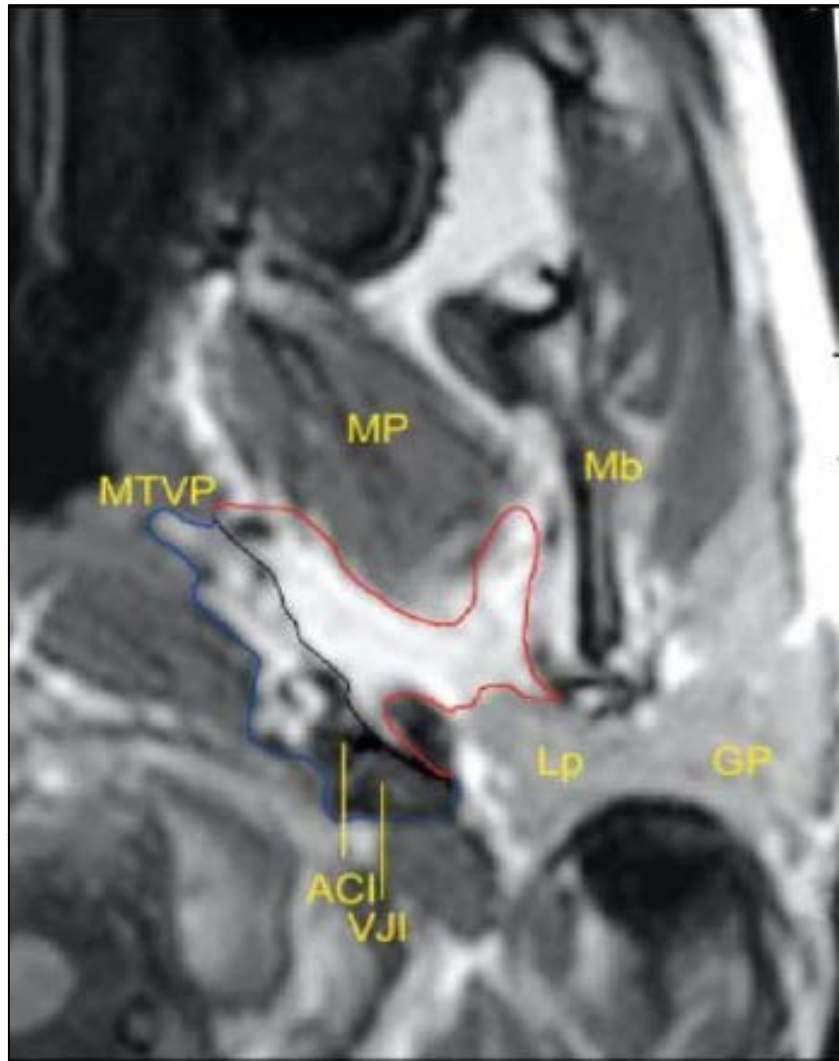
St. n. ACC 2000

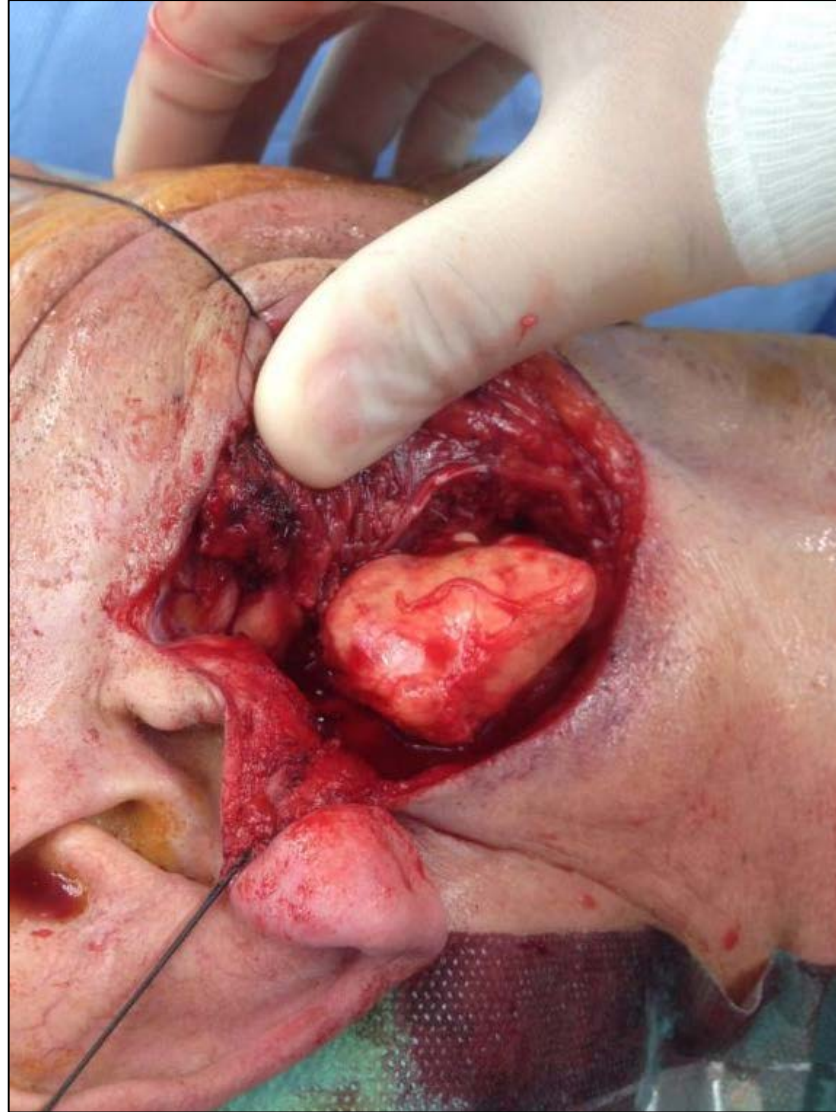

parotid lesions: deep lobe



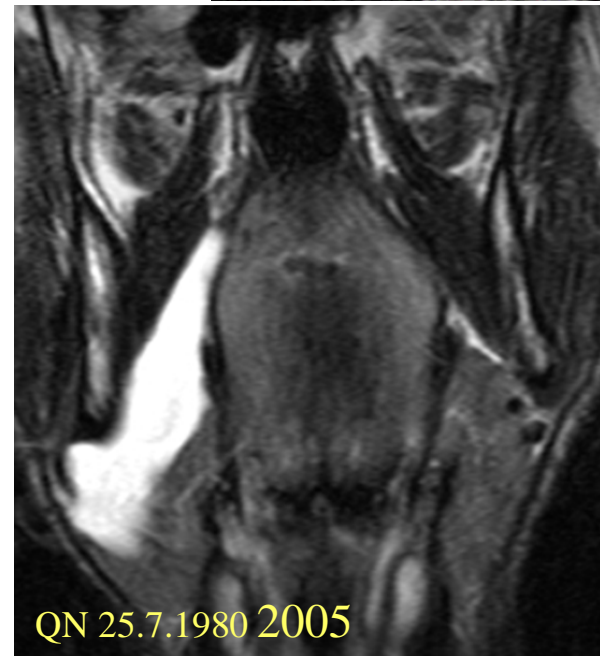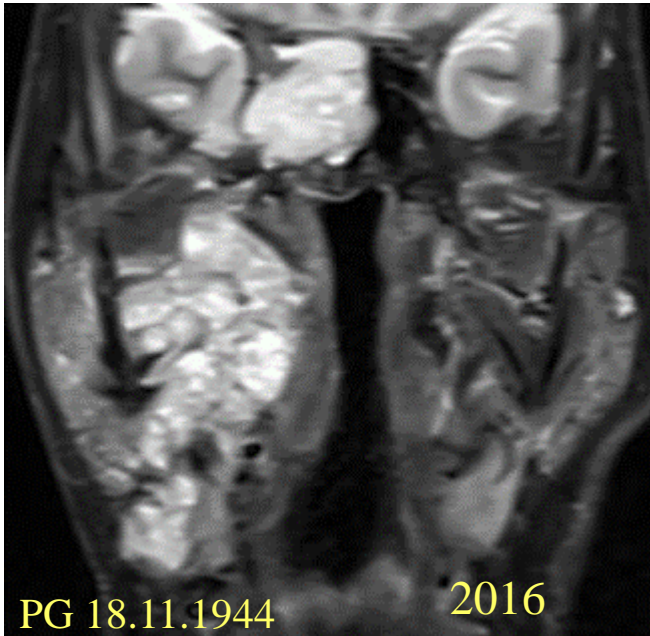
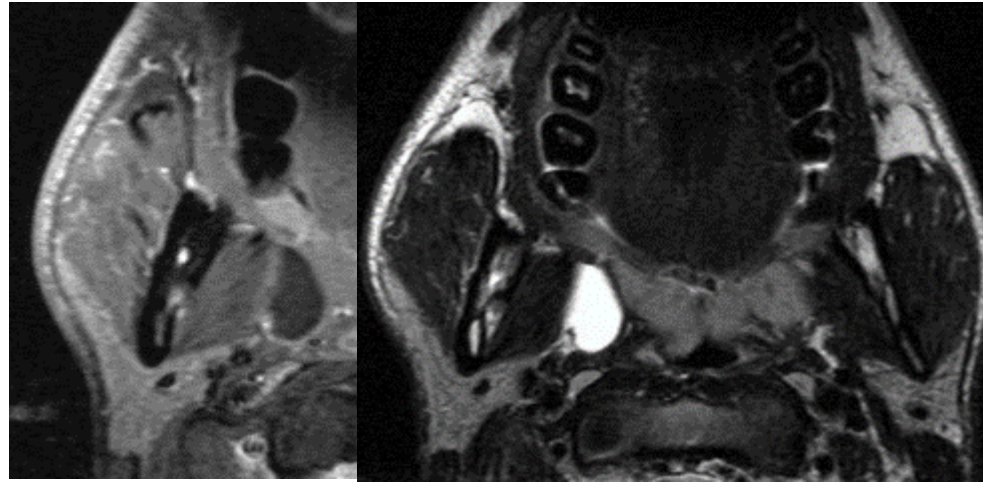
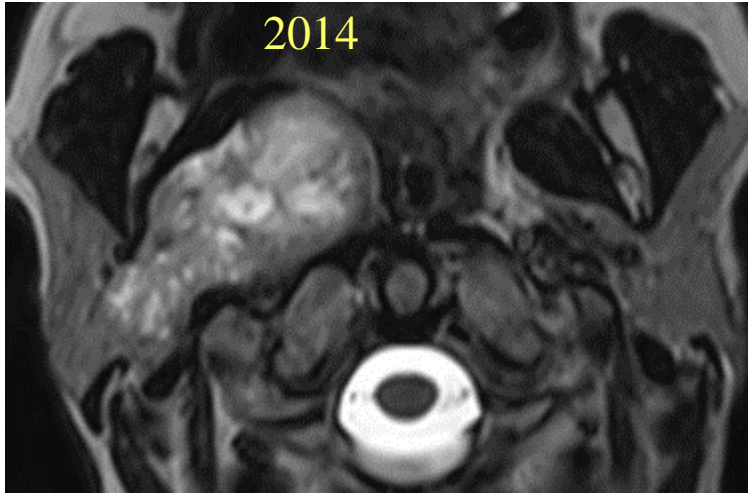
pre- or. poststyloidal compartment





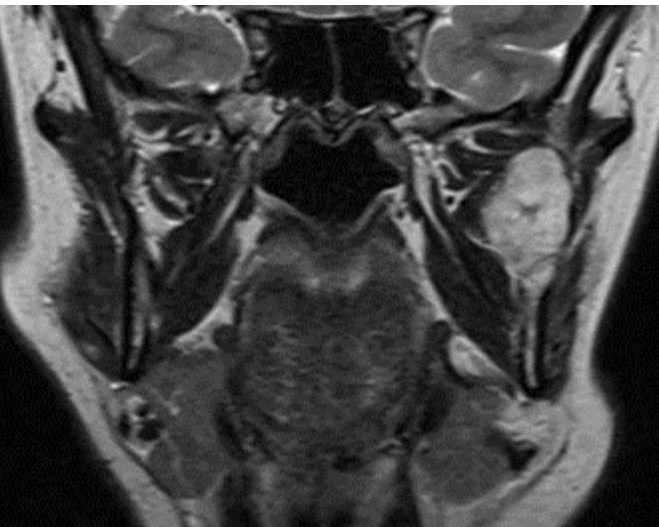
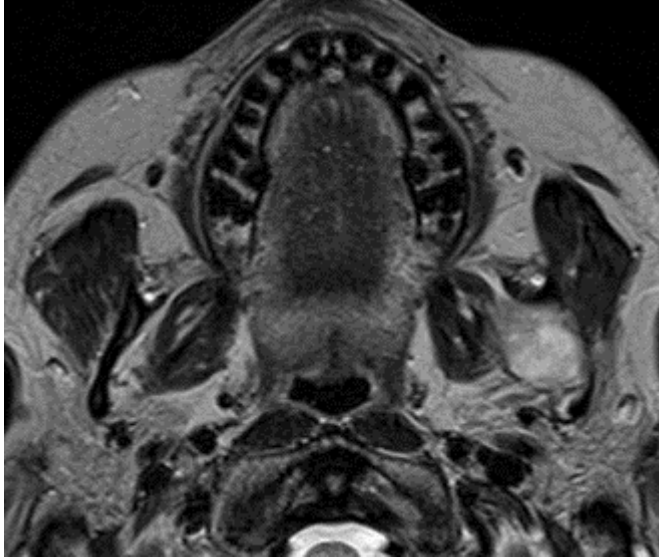parapharyngeal space lesions

extrinsic \leftrightarrow intrinsic

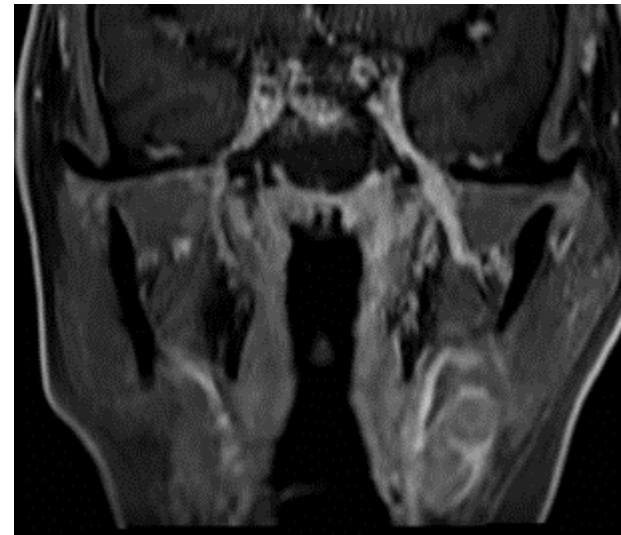
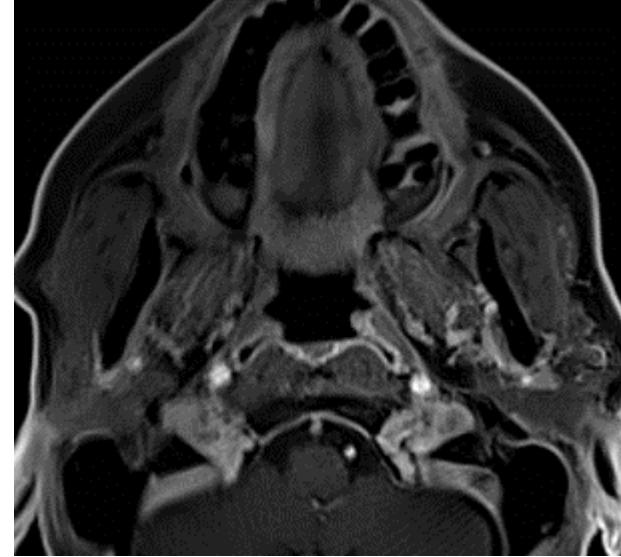


masticator space lesions

inferior alveolar nerve, neurinoma.

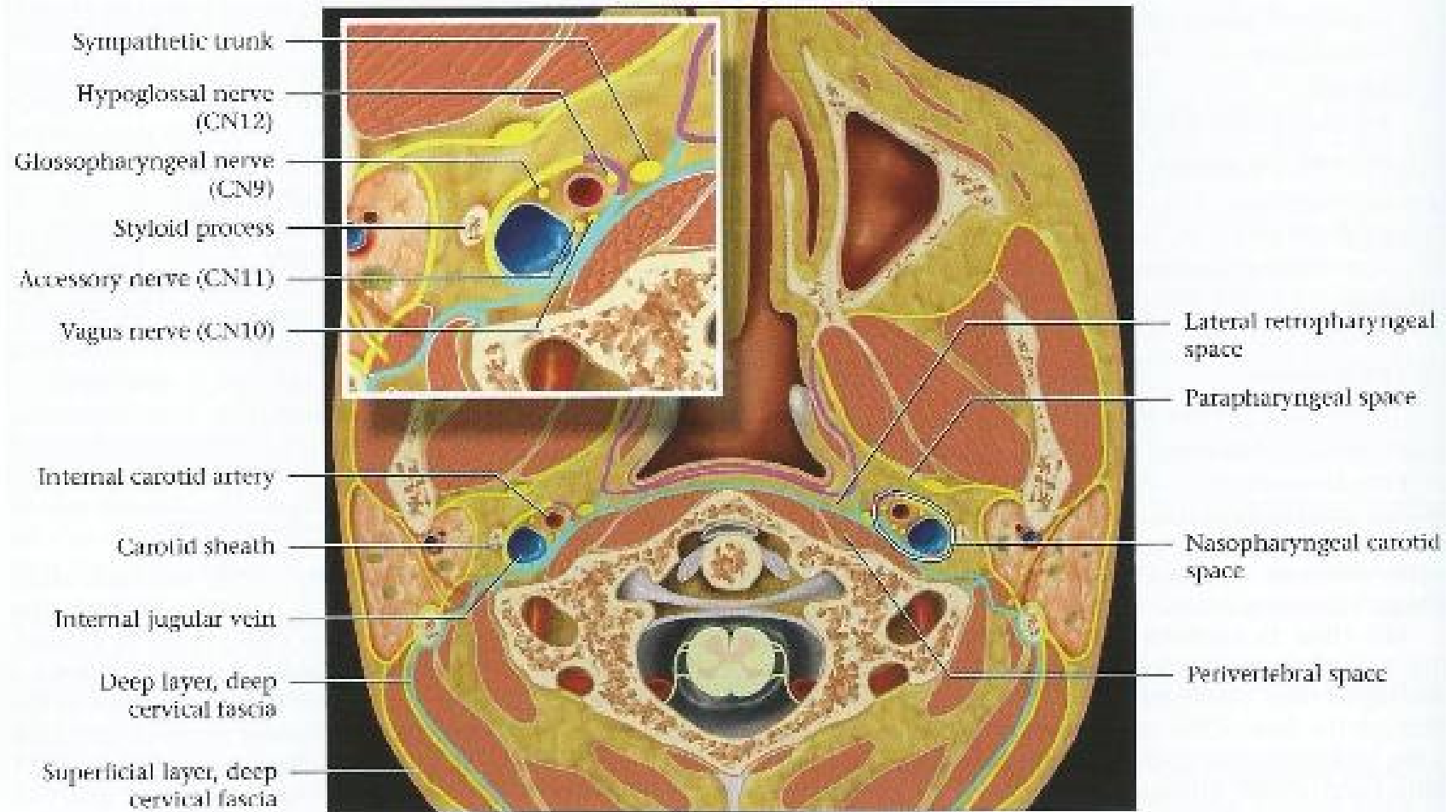


V3: perineural tu extension



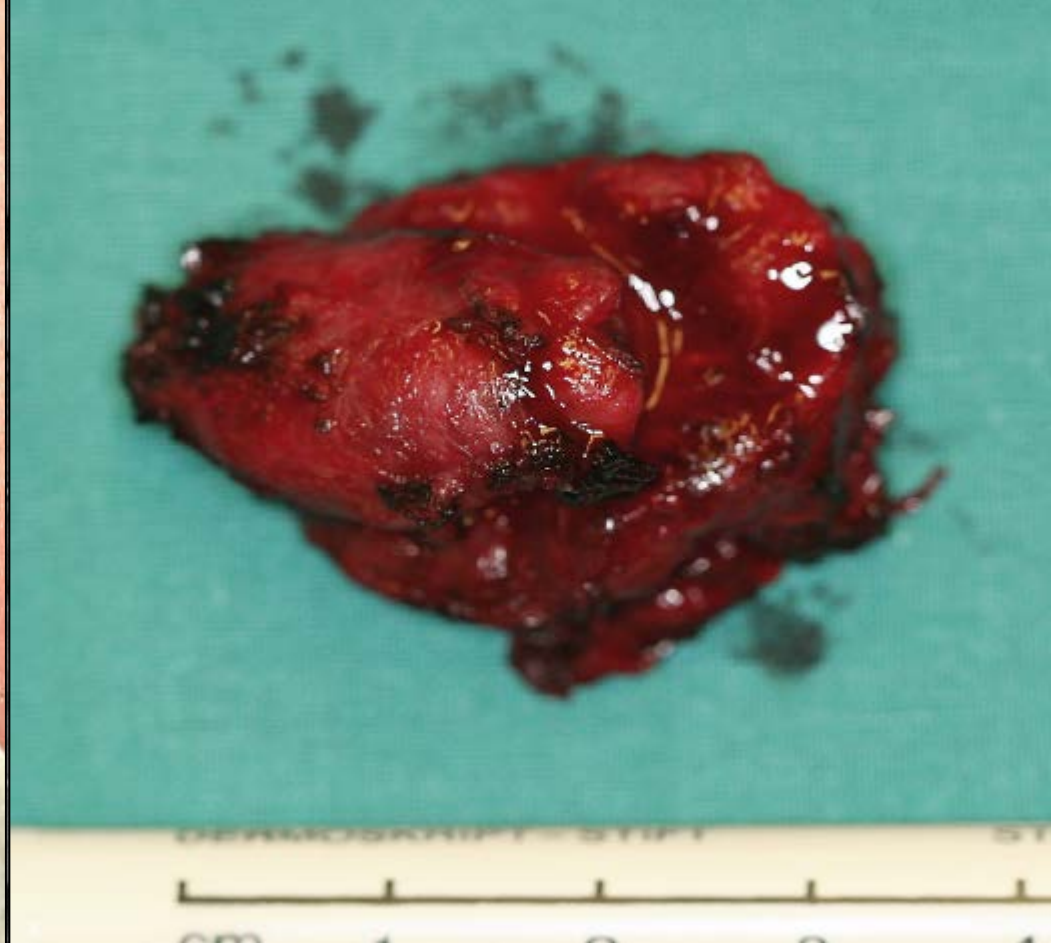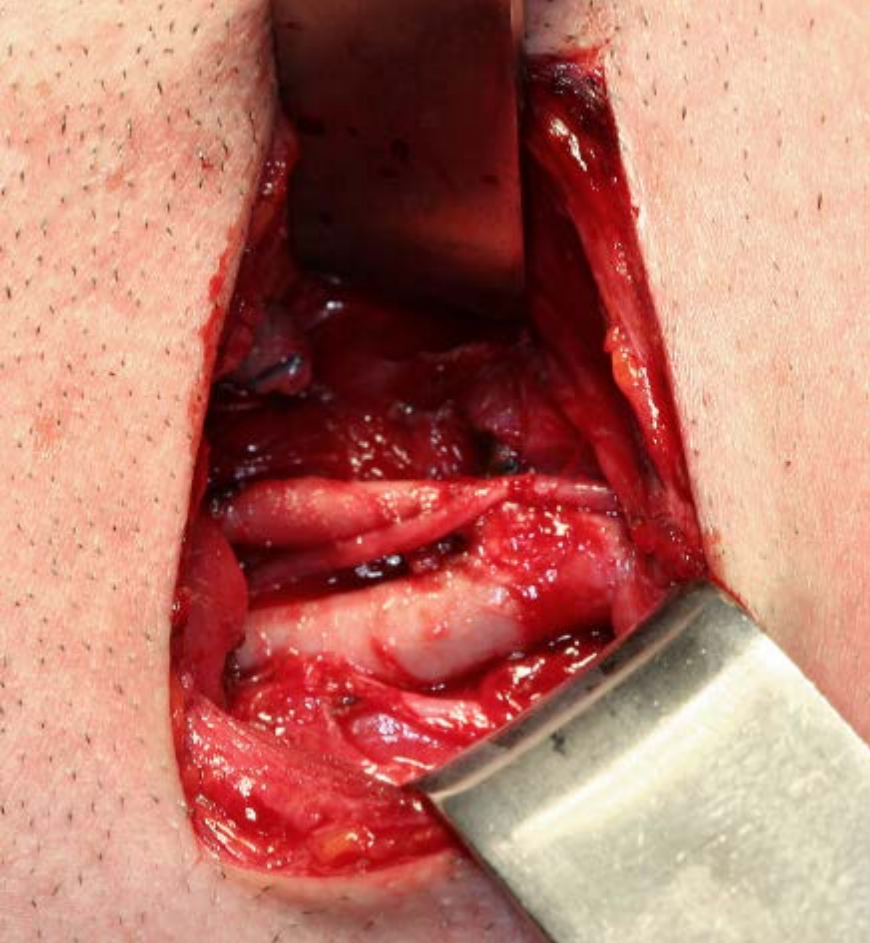

Target sign → schwannoma or neurofibroma

suprahyoidal carotid space

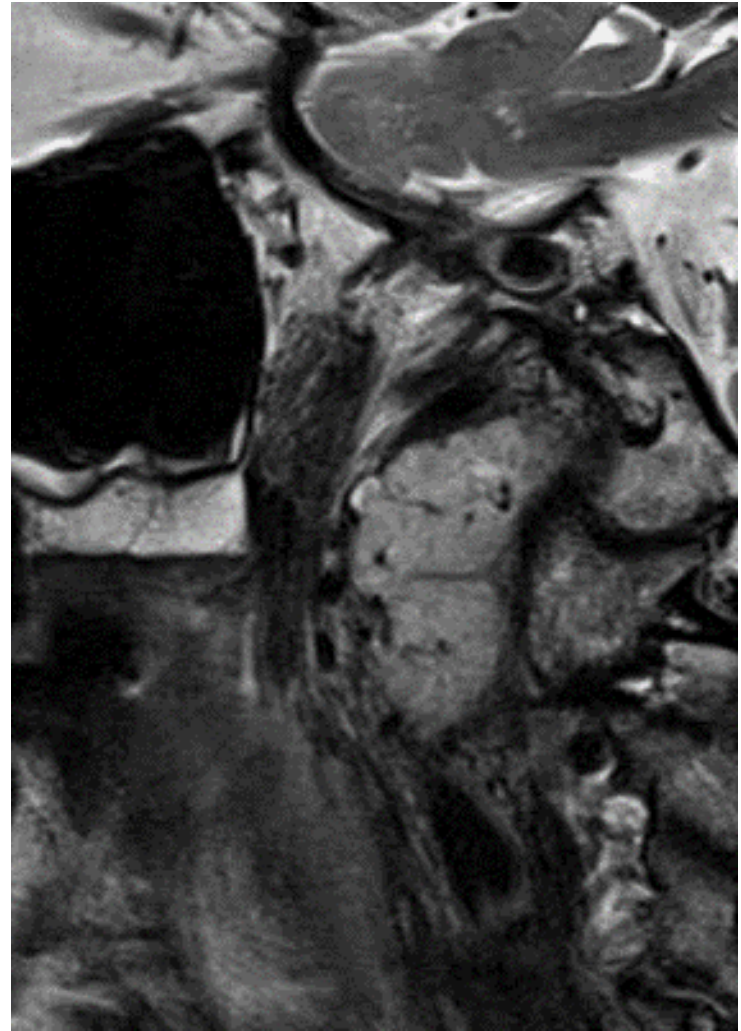

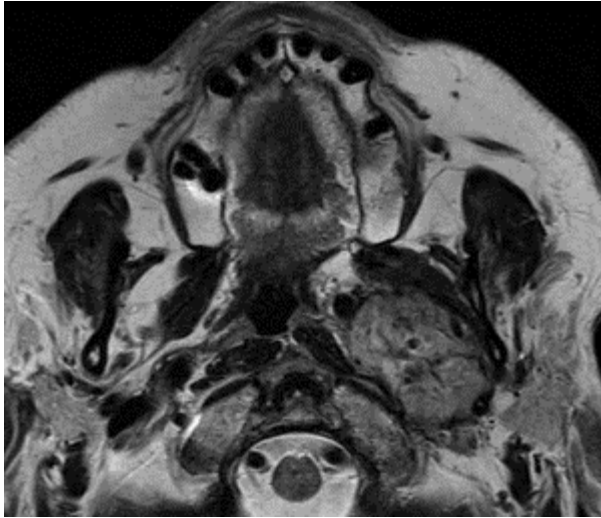


carotid space


Glomus
caroticum



carotid space



carotid space



- We only find what we look for,
- we only look for what we know,
- we know what to look for

if somebody tells us



Thank you for your attention!



„sleeping angler“ by Robert Seymour